



Marine Fisheries Information Service

Technical and Extension Series

Number 197

July - September 2008



Central Marine Fisheries Research Institute

(Indian Council of Agricultural Research)

Post Box No. 1603, Cochin - 682 018, Kerala, India

WWW.cmfri.org.in

On a sarcoma observed in *Epinephelus diacanthus*

B. B. CHAVAN, SUJIT SUNDARAM AND B. N. KATKAR

Mumbai Research Centre of CMFRI, Mumbai

Tumour seems to be a rare occurrence in marine fishes. An interesting case of endo-tumour was encountered in a male specimen of *Epinephelus*

diacanthus landed at New Ferry wharf on 20-10-06.

The fish measured 382 mm in total length and weighed 845 g. The tumorous outgrowth was round

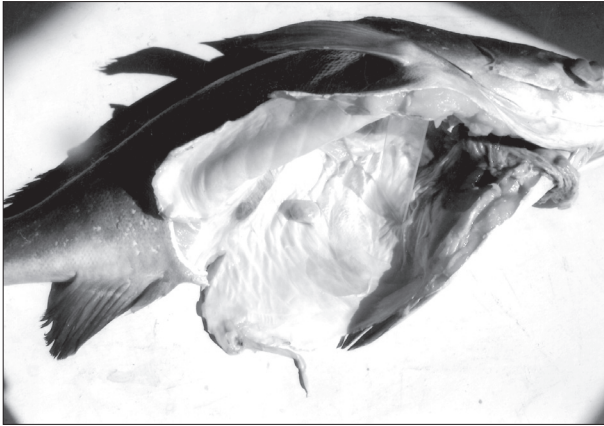


Plate 1 : Endo-tumour in *Epinephelus diacanthus*



Plate 2 : Close up of the endo tumour in *E. diacanthus*

shaped and was situated inside the abdominal cavity. The tumor measured 14.3 mm and weighed 2.448 g. It was grayish black in colour and was tough/soft in consistency. The tumor was connected to the body by connective tissue. The nature of the atypical growth could not be investigated.

A case of ecto-tumour was earlier reported from Mumbai in *Otolithes cuveri* (MFIS-183).

We are grateful to Dr. V. D. Deshmukh and Dr. Miriam Paul Sreeram for their constant encouragement.