



Note

Histological notes on protogynous hermaphroditism in the spinycheek grouper, *Epinephelus diacanthus* (Valenciennes, 1828)

A. Chandrasekhara Rao* and L. Krishnan

Central Marine Fisheries Research Institute, P.O. Box. 1603, Cochin-682018, Kerala, India

E-mail: phani_babu@rediffmail.com

Abstract

Histological studies on the gonads of *Epinephelus diacanthus* collected off Quilon and Ratnagiri west coast of India, revealed protogynous hermaphroditism and the presence of seven transitional stages. The transitional gonads were found to be intermixed with the spermatogonia and spermatocytes within the ovarian lamellae. The smallest size of the transitional *E. diacanthus* was 27.5 cm total length and the largest was 31.4 cm TL. The weight range was 362-430 g. Histologically recognized transitional *E. diacanthus* showed size related variations from the two geographically different regions.

Different types of reproductive modes exist among the teleosts. By far the most common mode is gonochorism. Certain groups of teleosts exhibit hermaphroditic type of reproduction. Hermaphroditism and gonadal sex inversion is a normal mode of reproduction in a number of serranids (Atz, 1964). Simultaneous hermaphrodites function concurrently as both male and female. In contrast, sequential hermaphrodites function as a male in one life phase and as a female in another (Warner, 1988).

Materials and methods

Live specimens of the spinycheek grouper, *Epinephelus diacanthus* were collected onboard Fishery Survey of India vessel during the cruises off Quilon (08° 55' N lat. and 76° 30' E long.) and Ratnagiri (15° 42' N lat. and 73° 16' E long.) from 50 m depth. Fishes were also collected from commercial trawlers operated off Quilon. A total of 182 fishes were collected during the period 2002-2004 and the gonads of 53 specimens were removed and preserved in Bouin's fixative for histological study. Gonad tissues which were preserved in the fixative were processed following the histological method of Weesner (1960). The histological sections (5 µm) were stained with haematoxylin and counter stained with eosin before examining under the light microscope.

Results and discussion

Histological investigations of the gonads revealed the presence of seven transitional stage gonads and the protogynous mode of reproduction in *E. diacanthus*. Of the 53 groupers examined histologically, 37 were females, seven were transitional individuals, and nine were males. Length and weight ranges of the specimens were 17.0 – 39.2 cm TL and 64 – 825 g for females and 28.3 – 47.2 cm TL and 368 – 1035 g for males. Seven transitional individuals were in the length range of 27.5 cm – 31.4 cm TL and weight in the range of 362 – 430 g. The lowest size transitional individual was observed in *E. diacanthus* at 27.5 cm total length. It is likely that from this size onwards *E. diacanthus* transforms from one sex to the other depending on the prevailing conditions. Tessy (1994) observed the transitional specimens in *E. diacanthus* at 30.2 cm standard length. Brule *et al.* (2000) also reported on the size related variations found in females, transitional individuals and males of *Epinephelus drummondhayi* from the southern Gulf of Mexico. In the present study, histologically recognized transitional individuals were collected during August-September. Ripe females and males were collected during April-May. It may be inferred that during the post-spawning months of August-September, transition

from one sex to the other may occur with the onset of favourable environmental and physiological factors.

Fishes collected from Ratnagiri and Quilon showed marginal difference in size in attaining transitional stages. Transition of sex occurred in smaller fishes off Quilon (TL = 28.1 ± 0.51 cm; N = 4) when compared to the fishes collected off Ratnagiri (TL = 30.5 ± 0.74 cm; N = 3).

Ovary in its early stages of transition into testis was observed in light microscopic examinations of histological slides. Moe (1969) described this stage as transitional stage. This stage is a temporary one. Microscopically, transitional gonads appeared similar to maturing female and male stages.

Histological studies of transitional gonads under stereomicroscopic observations revealed the presence of stages I and II and atretic oocytes. These oocytes were intermixed with spermatogonia and spermatocytes within ovarian lamellae. Ovary was observed with early stages of spermatogonial proliferation and degenerating oocytes (Fig.1). In later stages of male germ cell development with spermatocytes, some regressing oocytes were

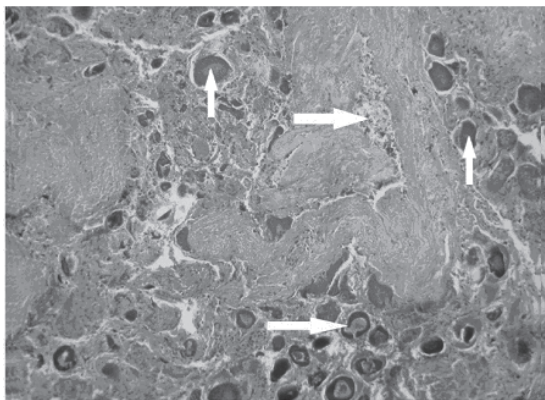


Fig. 1. Light micrograph of transitional stage ovary of *E. diacanthus* with regressing oocytes and spermatogonia (40 x); upper horizontal arrow indicates spermatogonia; lower horizontal arrow indicates regressing oocytes; right vertical arrow indicates stage I oocyte; left vertical arrow indicates stage II oocyte




Fig. 2. Light micrograph of *E. diacanthus* gonad with spermatocytes and regressing oocytes (20 x); arrow indicates regressing oocytes and asterisk indicates spermatocytes

noticed (Fig. 2). Brule *et al.* (1999) observed the presence of stage I and stage II oocytes with few scattered nests of spermatocytes or spermatozoa in the transitional gonads of *E. morio* collected off the Southern Gulf of Mexico. They also reported occasional presence of stage III oocytes in transitional gonads. Tessy (1994) observed the atretic oocytes with spermatogenic crypts in the transitional gonads of *E. diacanthus*.

As suggested by Smith (1965), the gonad of groupers is an admixture of ovarian and testicular tissues. He also pointed that protogynous mode of reproduction is common in a number of groupers in the family Epinephelinae. In the *E. diacanthus* gonads, the histological observations revealed the presence of *Epinephelus* type and protogynous mode of reproduction.

Histological observations of *E. diacanthus* ovary showed regressing oocytes with the proliferation of spermatogenic crypts. It indicated the presence of protogynous mode of reproduction in *E. diacanthus*. Brusle *et al.* (1989) reported seminiferous crypts scattered in the parietal part of ovarian lamella in protogynous hermaphroditic fish *E. microdon*. Some investigators believe that the identification of degenerative process inside the gonadal tissue reveals sex inversion (Moe, 1969; Abu-Hakima, 1987). In the present study much effort was not taken to study related aspects of physiology in relation to sex inversion.

Acknowledgements

The authors sincerely thank Prof. (Dr.) Mohan Joseph Modayil, Director, CMFRI, Cochin for extending facilities to carry out this work. The CIFE-ICAR fellowship granted to the first author's Ph. D. programme is gratefully acknowledged.

References

Abu-Hakima, R. 1987. *J. Fish. Biol.*, 30 (2): 213 – 222.
Atz, J. V. 1964. *In: Intersexuality in vertebrates including Man.* C. N. Armstrong and A. J. Marshall (Eds.) Academic Press, London, p.145-232.
Brule, T., C. Deniel, T. C. Marrufo and M. Sanchez-Crespo. 1999. *Transactions of the American Fisheries Society*, 128: 385 – 402.
Brule, T., T. C. Marrufo, A. T. Sulub and C. Deniel. 2000. *Bull. Mar. Sci.*, 66(2): 513 -521.

Brusle, S., L. Debas and C. Cauty. 1989. *Advances in Tropical Aquaculture*, p. 559-562.
Moe, M. A. 1969. *Florida Department of Natural Resources, Marine Research Laboratory, Professional Papers Series* 10, Florida, 95 pp.
Smith, C. L. 1965. *Am. Mus. Novit.*, 2207: 1 – 20.
Tessy, K. L. 1994. Studies on the biology of cultivable species of *Epinephelus* from the southwest coast of India. *Ph.D. Thesis*, Cochin University of Science and Technology, 219 pp.
Warner, R. R. 1988. *Environ. Biol. Fish.*, 22: 81 – 90.
Weesner, F. M. 1960. *General zoological microtechniques*, Williams and Wilkins company and scientific book agency, Calcutta, XII: 230 pp.

Received: 26 September 2007

Accepted: 11 December 2007