

Deformities recorded in fishes

*Swatipriyanka Sen, Gyanaranjan Dash and Indranil Mukherjee

Digha Research Centre of ICAR-Central Marine Fisheries Research Institute, Ramnagar- 721 441, West Bengal

*E-mail: swatipriyank1a@gmail.com

During regular field visits to Digha Mohana Fish landing centre (West Bengal, India) during August, 2018 to October, 2019 period, five abnormal fishes were collected and are recorded as given below. Deformed specimens of *Brevitrygon walga* and *Pateobatis bleekeri* (Rays), a deformed embryo of the shark *Scoliodon laticaudus*, guitarfish *Glaucostegus granulatus* and pomfret *Pampus argenteus* were recorded among the commercial landing. The rays were found to have rostral deformity. In case of *Brevitrygon walga* (Juvenile, Disc Width (DW) 14 cm), there was an incomplete fusion of both the left and right pectoral fin with the head, resulting in gap or cleft

between the pectoral fin and rostrum (Fig.1). In the case of *Pateobatis bleekeri* (Female adult, DW 120 cm), the deformity was seen in the rostral bone making the rostral part slightly elevated and curved (Fig.2). The embryo of *Scoliodon laticaudus* was found to have scoliotic, lordotic and kyphotic bends in the vertebral column. The body had a hump like structure behind the head and the rest of the trunk was rolled clockwise up to the caudal region. The eyes and gills were well developed in the cephalic region but the fins were malformed (Fig.3). In case of *Glaucostegus granulatus* (Two adult females, TL: 137cm and TL: 183 cm), the tail and rostral portions were found to be deformed



Fig.1. Rostral deformity in *Brevitrygon walga*

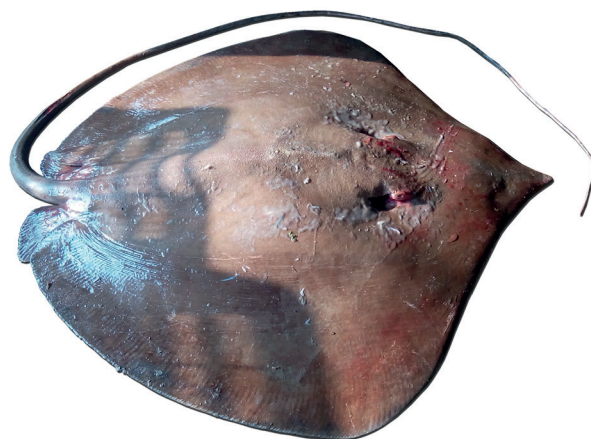


Fig.2. Rostral deformity in *Pateobatis bleekeri*

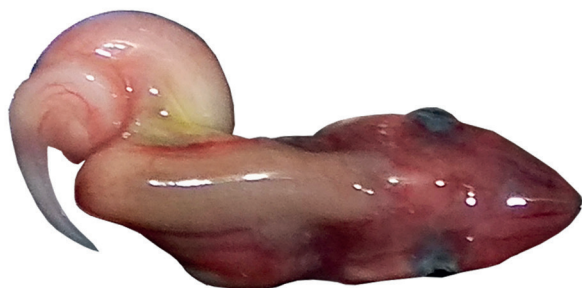

Fig.3. Deformed embryo of *Scoliodon laticaudus*



Fig.4. Deformity in the tail portion of *Glaucostegus granulatus*



Fig.5. Rostral deformity in *Glaucostegus granulatus*

(Fig.4 & 5). Both the dorsal fins and caudal lobes were poorly developed with the curved vertebrae of tail in the first specimen while the second one was having unfused pectoral fins to the snout forming clefts in both sides. The abnormalities in granulate guitar fish is recorded for the first time from India. Spinal scoliosis and abnormal curvatures in the vertebrae has been reported in several elasmobranch species (Moore, 2015). One specimen of Silver pomfret (*Pampus argenteus*, Standard Length (SL) 21.8 cm) was also observed to have an atrophied caudal fin without any dorsal and ventral lobes (Fig.6). This does



Fig.6. Caudal fin deformity in *Pampus argenteus*

not appear to have simply been inflicted during escaping from a predation attempt, mainly because of the fusion of both the upper and lower caudal lobes and absence of any scar tissue. The fusion of lobes indicates the possibilities of skeletal deformity toward the caudal portion. The cause of such deformities and its impact on the affected fishes need to be studied further.

References

Moore, A. B. M., 2015. *J. fish biol.*, 87: 465-471