

Loose shell syndrome (LSS) of cultured *Penaeus monodon* - microbiological and histopathological investigations

JAYASREE LOKA, P. JANAKIRAM*, G. K. GEETHA*, B. SIVAPRASAD* AND M. VEERENDRA KUMAR*

Karwar Research Centre of the Central Marine Fisheries Research Institute, Karwar - 581 301, Karnataka, India

*Department of Marine Living Resources, Andhra University, Visakhapatnam - 530 003, Andhra Pradesh, India

e-mail: lokasree@gmail.com

ABSTRACT

Investigations were undertaken on loose shell syndrome (LSS) of cultured *Penaeus monodon* during the period 2009 - 2010. The infected shrimps were collected from culture ponds of east and west Godavari districts in Andhra Pradesh, India and were subjected to microbiological and histopathological studies. Four species of *Vibrio* were isolated from the diseased shrimps and were identified as *V. harveyi*, *V. alginolyticus*, *V. metschnikovii* and *V. fluvialis* based on morphological characteristics and biochemical tests. Histopathological studies revealed the presence of occlusion and inclusion bodies of monodon baculovirus (MBV), hepatopancreatic parvo-like virus (HPV), and white spot syndrome virus (WSSV) in hepatopancreatic and gill tissues. All the LSS affected shrimps collected during the present study were found infected with *V. harveyi* and concurrent infections of other *Vibrio* species were observed in 40% of the samples. Prevalence of infection with WSSV, MBV and HPV was less compared to *Vibrio* infections. Granuloma formation was observed in the affected tissues due to bacterial invasions. Multiple viral infections in association with *Vibrio* sp. were also observed in 2% of LSS affected shrimp.

Keywords: Histopathology, Loose shell syndrome, Microbiology, *Penaeus monodon*

Introduction

Loose shell syndrome (LSS) is a serious disease problem of cultured *Penaeus monodon* in Andhra Pradesh, India. LSS affected shrimps exhibited symptoms like paper like carapace with a gap between the muscle tissue and carapace which turns into a soft leathery shell. The affected shrimps also exhibit reduction in weight throughout the culture period and the percentage of infection was maximum during summer season (Mayavu *et al.*, 2003). Gopalakrishnan *et al.* (2005) recorded LSS in all size groups of pond reared *P. monodon* and they also observed reduction in survival and growth rate due to this disease. Jayasree *et al.* (2006, 2008) reported that the LSS affected shrimps displayed clinical symptoms such as loose shell, soft muscle, condensed and melanised hepatopancreas, loss of appetite and erratic movements. They identified six *Vibrio* species associated with LSS affected shrimp of which, *Vibrio harveyi* was the most virulent. Prakasha *et al.* (2007) recorded Leam Singh virus (LSNV), white spot syndrome virus (WSSV), hepatopancreatic parvo like virus (HPV) and monodon baculovirus (MBV) in LSS affected *P. monodon*. Histopathological and bioassay studies made by Alavandi *et al.* (2007, 2008) revealed involvement of a filterable infectious viral like agent.

Although few investigations were carried out on bacterial and viral pathogens of LSS affected shrimp in India, the aetiology of LSS is still not known. The present article deals with microbiological and histopathological studies of LSS infected shrimp collected from east and west Godavari districts of Andhra Pradesh during 2009 - '10.

Materials and methods

Shrimps showing symptoms typical of LSS were collected from culture ponds situated in East (10 ponds) and west (10 ponds) Godavari districts of coastal Andhra Pradesh during 2009 - '10. From each pond, 10 samples with acute infection were transported to the laboratory in live condition and microbiological as well as histopathological investigations were undertaken. Haemolymph was drawn from each shrimp and plated on Tryptone Soya agar (TSA) and Thiosulphate Citrate Bile Sucrose agar (TCBS) to estimate total bacterial and total *Vibrio* counts respectively, following standard techniques (Lightner, 1996). Dominant bacterial colonies were purified by streak plate technique and identified following standard procedures (Baumann and Schubert, 1984; Lightner 1996). Pathogenicity studies were performed to test the virulence of bacterial isolates, by intramuscular injections with different bacterial concentrations ranging from 1×10^2 to

1×10^7 cfu ml⁻¹@0.01 ml g body weight⁻¹ to healthy juvenile shrimps having average weight of 5 g. Twenty numbers of healthy juvenile *P. monodon* were used for each experiment. Triplicates were maintained for each dose. For histopathological investigations, moribund shrimps were fixed in Davidson's fixative, processed, sectioned at 6 μ thickness and stained with haematoxylin and eosin following standard procedures (Lightner, 1996).

Results and discussion

Symptoms

Diseased shrimps were sluggish, weak with soft muscle, loose shell and with condensed and melanised hepatopancreas (Fig. 1). The affected shrimps exhibited erratic swimming behaviour and stopped feeding leading to mortalities. Similar symptoms were also recorded earlier by Mayavu *et al.* (2003), Gopalakrishnan and Parida (2005) and Jayasree *et al.* (2006, 2008). Alavandi *et al.* (2008) reported LSS as a slow progressive disease of farmed black tiger shrimp in India characterised by flaccid spongy abdomen caused by muscular dystrophy.



Fig. 1. *Penaeus monodon* affected with loose shell syndrome

Prevalence of disease

Data collected on the prevalence of LSS revealed that the infection is more in east Godavari District (32%) than in west Godavari district (18%) of Andhra Pradesh. Although mortality due to this infection was less, economic loss was very high. Mayavu *et al.* (2003) reported that 23% and 14% of farms in Tamil Nadu were affected with LSS during summer and winter seasons respectively. Earlier records of MPEDA/NACA (2003) showed that the incidence of LSS was about 27% in west Godavari District and 5% in Nellore District of Andhra Pradesh. In a survey of nearly 1100 ha farms near coastal Andhra Pradesh, it was recorded that more than 50% of the farms were affected with LSS (SAP, 2004).

Bacteriological analysis

Total bacterial loads of LSS affected haemolymph varied from 2.2×10^4 to 3.1×10^8 cfu ml⁻¹ in east Godavari District and 1.1×10^3 to 4.3×10^6 cfu ml⁻¹ in west Godavari District. Total *Vibrio* counts (TVC), with a maximum value of 5.8×10^6 cfu ml⁻¹ and minimum value of 1.2×10^3 cfu ml⁻¹ were observed in samples of east Godavari District (Table 1). Jayasree *et al.* (2006) recorded heavy *Vibrio* loads with an average of 0.1×10^6 cfu ml⁻¹ from LSS affected shrimps collected during the period 2001-2003 from East Godavari District of Andhra Pradesh. Mayavu *et al.* (2003) also observed high *Vibrio* loads in tissues of LSS infected animals and identified four *Vibrio* spp. with *V. alginolyticus* as dominant species. In the present study, four *Vibrio* species viz., *V. harveyi*, *V. alginolyticus*, *V. metschnikovii* and *V. fluvialis* were identified from diseased shrimps (Table 2). The present study revealed *V. harveyi* as the most dominant species followed by *V. alginolyticus* among the 150 *Vibrio* isolates from LSS affected shrimps. *Vibrio harveyi* was found in all diseased shrimps collected from

Table 1. Total bacterial and *Vibrio* counts recorded in haemolymph of LSS affected shrimps collected from shrimp farms in Andhra Pradesh

Pond No.	East Godavari District		West Godavari District	
	Total bacterial count (cfu ml ⁻¹)	Total <i>Vibrio</i> count (cfu ml ⁻¹)	Total bacterial count (cfu ml ⁻¹)	Total <i>Vibrio</i> count (cfu ml ⁻¹)
1	4.21×10^4 - 1.1×10^6	1.8×10^3 - 1.5×10^4	1.1×10^3 - 0.2×10^5	0.14×10^2 - 4.3×10^4
2	3.1×10^4 - 1.8×10^6	3.2×10^3 - 3.2×10^4	0.2×10^4 - 0.62×10^5	0.2×10^1 - 0.3×10^3
3	3.6×10^6 - 2.8×10^8	2.4×10^4 - 4.6×10^6	0.11×10^5 - 4.3×10^6	0.51×10^2 - 3.1×10^3
4	2.2×10^4 - 4.3×10^5	0.6×10^2 - 2.1×10^3	0.21×10^3 - 0.42×10^5	0.14×10^1 - 0.8×10^3
5	3.5×10^6 - 2.3×10^7	1.2×10^3 - 3.7×10^5	0.46×10^5 - 0.21×10^6	0.6×10^2 - 0.11×10^4
6	2.1×10^6 - 3.1×10^8	0.2×10^5 - 5.8×10^6	0.42×10^4 - 0.63×10^5	0.23×10^2 - 0.62×10^3
7	0.22×10^5 - 1.4×10^6	2.14×10^3 - 2.6×10^3	1.5×10^3 - 3.2×10^5	1.4×10^1 - 1.7×10^3
8	2.5×10^4 - 3.2×10^7	1.4×10^3 - 1.2×10^5	0.6×10^4 - 0.14×10^6	0.14×10^2 - 0.42×10^4
9	0.41×10^5 - 2.3×10^8	0.72×10^4 - 3.1×10^6	0.17×10^4 - 2.8×10^6	2.1×10^2 - 5.1×10^4
10	3.14×10^4 - 4.4×10^6	3.8×10^3 - 0.72×10^4	0.26×10^4 - 0.33×10^6	1.8×10^1 - 3.4×10^4

Table 2. Morphological and biochemical characteristics of bacterial isolates from loose shell syndrome affected shrimps

Name of the test	Isolate 1 (<i>V. h</i>)	Isolate 2 (<i>V. alg</i>)	Isolate 3 (<i>V. fluv.</i>)	Isolate 4 (<i>V. metch</i>)
Gram's staining	-	-	-	-
Shape	Rod	Rod	Rod	Rod
Motility	+	+	+	+
Oxidase	+	+	+	-
Catalase	+	+	+	+
O/F test	F	F	F	F
Acid production from glucose	+	+	+	+
NaCl tolerance test				
2%	+	+	+	+
4%	+	+	+	+
6%	+	+	+	+
8%	+	+	+	+
10%	+	+	+	+
Temperature tolerance test				
4 °C	-	-	-	-
20 °C	+	+	+	+
30 °C	+	+	+	+
40 °C	+	+	+	+
Decarboxylation of amino acids				
Arginine	-	-	+	+
Ornithine	+	+	-	+
Lysine	+	+	-	-
MRVP test	+	+	+	+
VP test	-	+	-	+
Indole test	+	+	-	-
Starch hydrolysis	+	+	-	-
Urea hydrolysis	+	+	+	+
Esculin hydrolysis	-	-	+	+
Gelatin liquefaction	-	+	+	+
Utilisation of carbohydrates				
L-Arabinose	+	-	+	-
Dextrose	+	+	+	+
Fructose	+	+	+	+
Lactose	-	-	-	+
Mannose	+	-	+	-
Galactose	+	+	+	-
Sucrose	+	+	+	+
Trehalose	+	+	+	+
Cellobiose	+	-	+	-
Melibiose	-	-	-	-
Salicin	+	-	+	-
Xylose	-	-	-	-
Citrate utilisation	+	+	+	-
Nitrate reduction	+	+	+	-
ONPG hydrolysis	+	-	+	-
Growth on TCBS	Y	Y	Y	G
Inhibition by 0/129 phosphate				
10 µg	R	R	R	S
150 µg	S	S	S	S
Luminescence	+	-	-	-

V. h = *Vibrio harveyi*, *V. alg.* = *V. alginolyticus*, *V. fluv.* = *V. fluvialis*, *V. metch* = *V. metschnikovii*

both east and west Godavari districts. *V. alginolyticus* was identified in 32% and 24% of shrimps from east Godavari and west Godavari districts respectively (Fig. 2). Occurrence of *V. fluvialis* and *V. metschnikovii* was rare. Jayasree *et al.* (2006, 2008) identified six *Vibrio* species from LSS affected shrimp among which the prevalence of infection with *V. harveyi* was 100%.

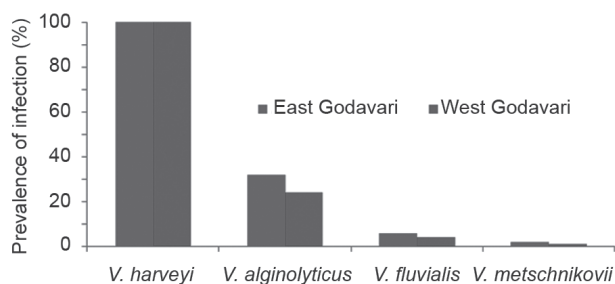


Fig. 2. Prevalence of *Vibrio* infections in LSS affected shrimps

Pathogenicity studies

Pathogenicity studies revealed *V. harveyi* as the most pathogenic species among all the *Vibrio* spp. isolated from LSS affected shrimps with LC_{50} value of 1×10^5 cfu g^{-1} (Fig. 3) followed by *V. alginolyticus*, *V. fluvialis* and *V. metschnikovii*. Of all the *Vibrio* isolates, *V. harveyi* was found to be the most virulent species recorded during the present study and also in earlier studies by Jayasree *et al.* (2008) with a slight variation in its virulence. The LC_{50} value of *V. harveyi* recorded earlier by Jayasree *et al.* (2008) was 1×10^3 cfu g^{-1} . Mayavu *et al.* (2003) recorded *V. alginolyticus* isolated from LSS affected shrimp as the most dominant and virulent species.

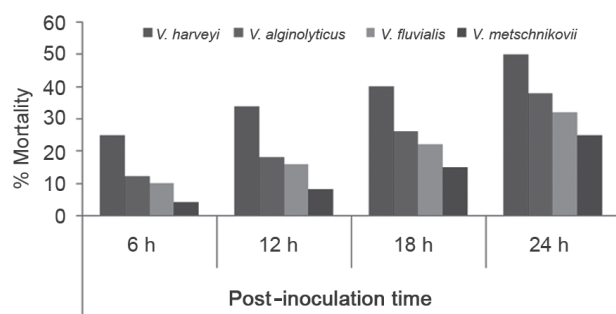


Fig. 3. Virulence of *Vibrio* spp. isolated from LSS affected shrimp

Histopathology

Histopathological studies revealed bacterial septicaemia leading to condensation of hepatopancreatic (HP) tubules (Fig. 4a), melanised granulomas of different sizes (Fig. 4b), vacuolation of HP cells and haemocytic

infiltration (Fig. 4c). Hepatopancreatic tubules appeared highly necrotic with thickened tubular sheath and enlarged intertubular space (Fig. 4d). The epithelial cells showed presence of hypertrophied and pyknotic nuclei (Fig. 4e). Alavandi *et al.* (2008) also observed inflammation of hepatopancreatic tubules with enlargement of intertubular spaces and hemocytic infiltration in tissue sections of LSS affected shrimp. They reported presence of completely sloughed HP tubules and severe necrosis of HP in LSS affected shrimp. These pathological changes are indication of impairment of the hepatopancreas and its metabolic activity. Presence of hemocytic infiltration in the space between the tubules of the gill, the melanised nonfunctional tubules in the gill lamellae, intranuclear inclusion bodies in intestine, necrosis of intestinal wall, atrophied HP tubular cells and absence of storage vacuoles was noticed by Gopalakrishnan and Parida (2005) in LSS affected shrimp. They stated that the absence of storage vacuoles is due to prolonged starvation of the animal in the pond. Similar types of changes in the sections of hepatopancreatic tissues were observed in the present study also. Mayavu *et al.* (2003) noticed presence of inclusion bodies in the histological sections of gills, gut and abdomen of LSS affected shrimp. Baticados *et al.* (1987) observed compression and disruption of HP tubules and enlargement of lumen in the soft shell affected shrimp.

Histopathological studies of the present investigation also revealed the presence of HPV, MBV and WSSV infections in the sections of hepatopancreas and gills of LSS affected shrimp. Cowdry-type basophilic intranuclear inclusion bodies typical of WSSV were observed in the gill sections of LSS affected shrimp (Fig. 4f). Presence of polyhedral eosinophilic occlusion bodies in the cells of hepatopancreas which is a characteristic feature of MBV, was detected in the sections of hepatopancreatic tissues (Fig. 4g). Presence of HPV was detected in HP sections of LSS affected *P. mondon* and was characterised by the occurrence of basophilic intranuclear inclusion bodies with crescent shaped nuclei pushed to one side (Fig. 4h). Prakasha *et al.* (2007) observed the presence of infectious hypodermal and hematopoietic necrosis virus (IHHNV), HPV, MBV, LSNV and WSSV in LSS affected shrimp.

Prevalence of infection with WSSV, MBV and HPV was lower compared with the *Vibrio* infections. In East Godavari District, 16% of LSS affected shrimp collected during the present investigation exhibited WSSV infection, whereas, 18% were infected with HPV and 10% with MBV infections. Double infections in LSS infected shrimp, like WSSV and MBV, WSSV and HPV and HPV and MBV were found to be 2%, 4% and 8% respectively. Multiple viral infections with WSSV, MBV and HPV in association with *Vibrio* infections were observed in 2% of LSS affected

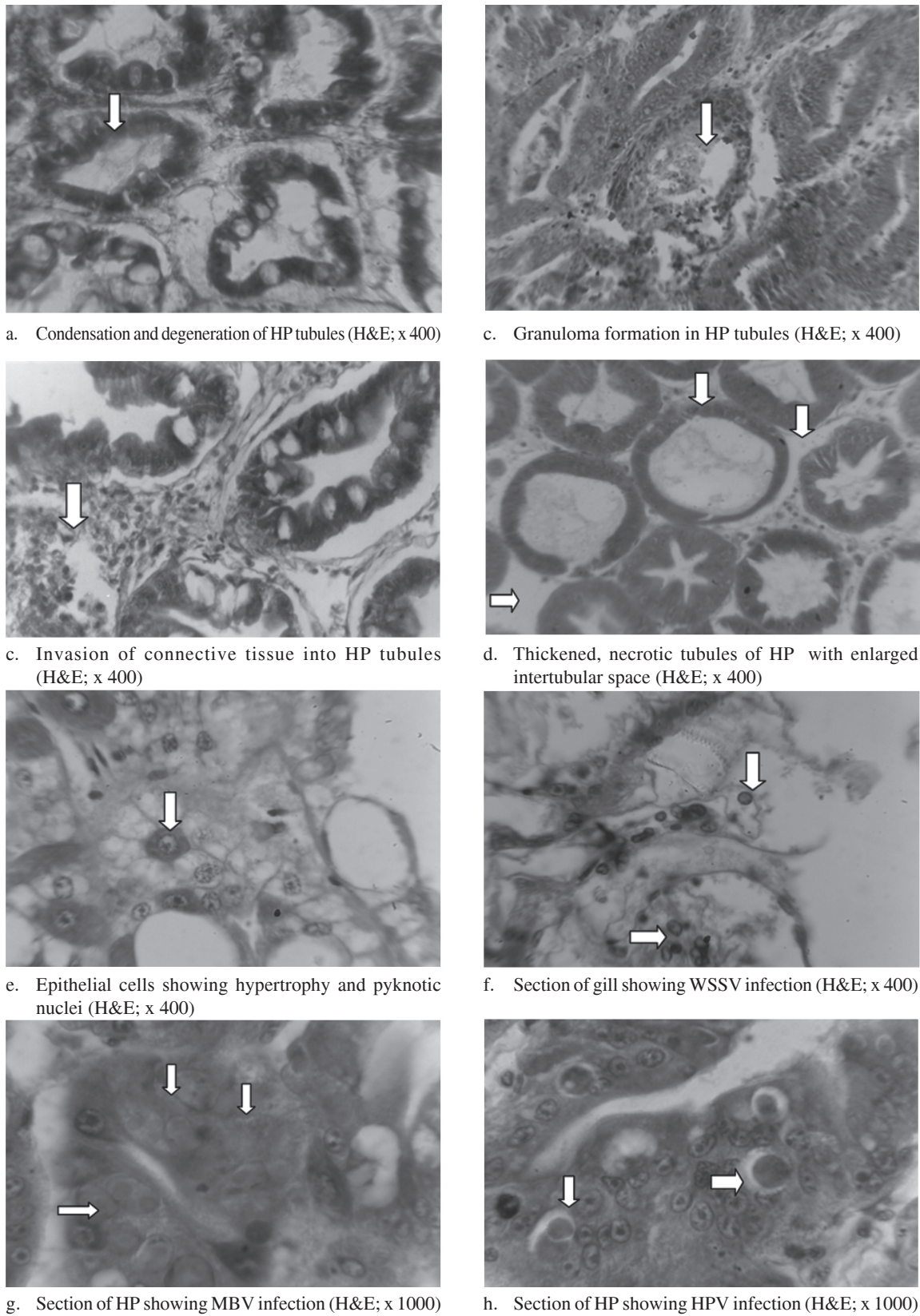


Fig. 4 a-h. Histological sections of various tissues of LSS affected shrimps

shrimps. In West Godavari District, the percentage of viral infection in infected shrimp was less compared to East Godavari District (Fig. 5). Sittidilokratna *et al.* (2009) recorded 56.8% of prevalence of LSNV infection in cultured *P. monodon* but the infection in association with LSS is not clearly noticed. Prakasha *et al.* (2007) recorded co-occurrence of LSNV, WSSV, HPV and MBV in LSS affected shrimps. In recent years, many new viral pathogens have been reported as causative agents of emerging diseases of cultured shrimps from different geographical regions (Fraser and Owens, 1996; Costa *et al.*, 1998; Poulos *et al.*, 2006; Sritunyalucksana *et al.*, 2006). Alvandi *et al.* (2008) reported involvement of a filterable infectious agent as causative factor for LSS in farmed tiger shrimp in India. The present investigation revealed the presence of both *Vibrio* and viral infections in LSS affected shrimp but their prevalence varied from area to area which could be due to variations in environmental parameters in the respective areas. Although the causative agent of LSS is not yet clearly identified, the occurrence of many bacterial and viral pathogens indicate that the incidence of LSS is a serious issue for the shrimp culture industry which needs to be addressed giving emphasis to environmental management.

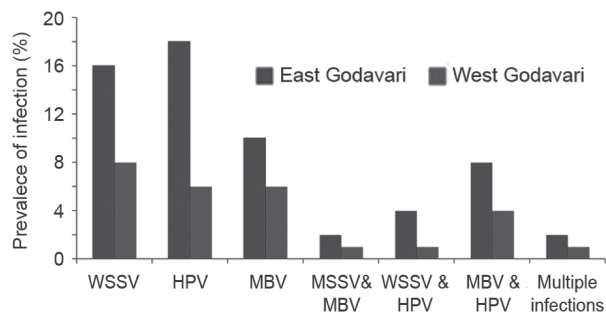


Fig. 5. Prevalence of viral infections in LSS affected shrimp

Acknowledgements

The authors are grateful to the Department of Science and Technology, Government of India, New Delhi for providing financial assistance to carry out this work.

References

- Alavandi, S.V., Babu, T. D., Abhilash, K. S., Kalaimani, N., Chakravarthy, N., Santiago, T. C. and Vijayan, K. K. 2007. Loose shell syndrome causes low-level mortality in India's black tiger shrimp. *Glob Aquac Advocate*, 10: 80–81.
- Alavandi, S. V., Babu, T. D., Abhilash, K. S., Vijayan, K. K., Kalaimani, N. And Santiago, T. C. 2008. Loose shell syndrome of farmed *Penaeus monodon* in India is caused by a filterable agent. *Dis. Aquat. Org.*, 81: 163-171.
- Baticados, M. C. L., Coloso, R. M. and Duremdez, R. C. 1987. Histopathology of the chronic soft shell syndrome in the tiger prawn *Penaeus monodon*. *Dis. Aquat. Org.*, 3: 13–28
- Baumann, P. and Schubert, R. H. W. 1984. Vibrionaceae Veron. In: Krieg, N. R. and Holt, J. G. (Eds.), *Bergey's manual of systematic bacteriology*. Williams and Wilkins, Baltimore, Maryland, USA, p. 516–550.
- Costa, R., Mermoud, I., Mari, J., Bonami, J. R., Hasson, K. and Lightner, D. V. 1998. Investigations of *Penaeus stylirostris* disease syndrome 93 in New Caledonia, exploring a viral hypothesis. *Aquaculture*, 164: 311–322.
- Fraser, C. A., and Owens, L. 1996. Spawner-isolated mortality virus from Australian *Penaeus monodon*. *Dis. Aquat. Org.*, 27: 141–148.
- Gopalakrishnan, A. and Parida, A. 2005. Incidence of loose shell syndrome disease of the shrimp *Penaeus monodon* and its impact in the grow-out culture. *Curr. Sci.*, 88: 1148–1154.
- Jayasree, L., Janakiram, P. and Madhavi, R. 2006. Characterisation of *Vibrio* spp. associated with diseased shrimp from culture ponds of Andhra Pradesh (India). *J. World Aquacult. Soc.*, 37(4): 523-532.
- Jayasree, L., Janakiram, P. and Madhavi, R. 2008. Isolation and characterisation of bacteria associated with cultured *Penaeus monodon* affected by loose shell syndrome. *Isr. J. Aquacult. Bamidgeh*, 60 (1): 46-56.
- Lightner, D. V. 1996. *A handbook of pathology and diagnostic procedures for diseases of penaeid shrimp*. Department of Veterinary Science, University of Arizona, Tucson, AZ.
- Mayavu, P., Purushothaman, A. and Kathiresan, K. 2003. Histology of loose-shell affected *Penaeus monodon*. *Curr. Sci.*, 85: 1629–1634.
- Mohan, C. V., Shankar, K. M., Kulkarni, S., Sudha, P. M.. 1998. Histopathology of cultured shrimp showing gross signs of yellow head syndrome and white spot syndrome during 1994 Indian epizootics. *Dis. Aquat. Org.*, 34: 9 -12.
- MPEDA/NACA (Marine Products Export Development Authority/Network of Aquaculture Centres in Asia-Pacific) 2003. *Shrimp health management extension manual*. Available at: <http://library.enaca.org/Shrimp/manual/Shrimp Health Manual.pdf>.
- Nunan, L. M., Poulos, B., Redman, R., Le Groumellec, M. and Lightner, D. V. 2003. Molecular detection methods developed for a systemic rickettsia-like bacterium (RLB) in *Penaeus monodon* (Decapoda: Crustacea). *Dis. Aquat. Org.*, 53:15–23.
- Poulos, B. T., Tang, K. F. J., Pantoja, C. R. , Bonami, J. R. and Lightner, D. V. 2006. Purification and characterisation of infectious myonecrosis virus of penaeid shrimp. *J. Gen. Virol.*, 87: 987–996.
- Prakasha, B. K., Ramakrishna, R. P., Karunasagar, I. and Karunasagar, I. 2007. Detection of Laem-Singh virus (LSNV) in cultured *Penaeus monodon* from India. *Dis. Aquat. Org.*, 77: 83–86.

SAP (Society of Aquaculture Professionals) 2004. *Proceedings of the workshop on loose shell problem in farmed black tiger shrimp*, Chennai, 28 April 2004.

Sittidilokratna, N., Dangtip, S., Sritunyalucksana, K., Ravi Babu, Pradeep, P., Mohan, C. V., Gudkovs, N. and Walker, P. J. 2009. Detection of Laem-Singh virus in cultured *Penaeus*

monodon shrimp from several sites in the Indo-Pacific region. *Dis. Aquat. Org.*, 84: 195–200.

Sritunyalucksana, K., Apisawetakan, S., Boon-nat, A., Withyachumnarnkul, B. and Flegel, T. W. 2006. A new RNA virus found in black tiger shrimp *Penaeus monodon* from Thailand. *Virus Res.*, 118: 31–38.

Date of Receipt : 30.03.2012
Date of Acceptance : 16.08.2012