

Note

Microsporidian (*Glugea* sp.) infection in the greasy grouper *Epinephelus tauvina* (Forsskal, 1775)

K. P. JITHENDRAN, K. K. VIJAYAN* AND M. KAILASAM

Aquatic Animal Health and Environment Division, Central Institute of Brackishwater Aquaculture
75, Santhome High Road, R. A. Puram, Chennai - 600 028, Tamil Nadu, India

* Division of Marine Biotechnology, Central Marine Fisheries Research Institute, Kochi - 682 018 Kerala, India

e-mail: kpjithendran@yahoo.com

ABSTRACT

A case of microsporidian (*Glugea* sp.) infection in the greasy grouper, *Epinephelus tauvina* (Forsskal) was studied by light microscopy as well as histological examination. The parasite was located in the subcutaneous tissue and visceral organs, forming spherical blackish xenomas of about 1-2.5 mm in diameter surrounded by a layer of connective tissue. The observed characteristics of the parasite are in line with those of the other *Glugea* species; showing merogony in the outer zone of the cytoplasm of the host cell, sporogony in sporophorous vesicles, and mature ovoid spores 4-6.5 μm x 2-2.2 μm located in the central part of the blackish xenoma. These characteristics suggested that the microsporidian which was found to infect *E. tauvina* during the present investigation was *Glugea* sp.

Keywords: *Epinephelus tauvina*, *Glugea* sp., Greasy grouper, Microsporidia, Xenoma

Microsporidia are a large group of obligate eukaryotic intracellular parasites represented by 144 genera (18 of them from teleosts) comprising over 1200 species reported so far, including 156 species from fish (Lom and Nilsen, 2003; Casal *et al.*, 2009). The main diagnostic stage of the parasite is the minute unicellular spores measuring 3-10 μm , with a single coiled polar filament. Often they form small pea-sized nodules of different shapes and colour on the affected tissues which are filled with pear-shaped transparent spores. The growth and proliferation of the microsporidian within the host cell results in complete destruction of the cells. The developmental stages and mature spores gradually replace the cell contents until the host cell becomes a mere envelope containing the parasites. Host tissue is damaged by pressure atrophy, which elicits proliferation of the connective tissue around the parasite mass, forming a parasite-hypertrophic host cell complex, the xenoma (Lom and Dykova, 1992; Lom and Nilsen, 2003). Among grouper fishes (*Epinephelus* spp.) this infection has been reported from China and Philippines (Nagasawa and Cruz-Laceierda, 2004; Zhang *et al.*, 2004; Wu *et al.*, 2005). In the present communication, we report the occurrence of *Glugea* sp. in the visceral organ of the greasy grouper, *Epinephelus tauvina* based on light microscopy and histology. A description of the parasite and its clinicopathology in the host fish are given.

Greasy groupers (*E. tauvina*) weighing 2.5 to 4.0 kg (mean length, 28.5 + 8.5 cm and weight, 2.82 + 1.12 kg),

originally caught from Muttukkadu coastal waters near Chennai (Tamil Nadu) and maintained in RCC cement tank (100 t capacity) for the captive broodstock development programme of the Institute were presented for disease investigation upon mortality during 2000-2002. The dead fishes from the stock were subjected to post-mortem examination at the aquatic animal health laboratory of the Institute. Few fishes showed exophthalmia and mild skin abrasions. On examination, the visceral organs (*viz.*, intestinal wall, pyloric caecae and associated fat tissue) revealed oval or round blackish nodules of varying size measuring 1-2.5 mm in diameter. Squash preparations of these nodules were examined fresh as well as after staining with Giemsa stain. Post-mortem examination revealed pale liver, enlarged swimbladder, relatively empty stomach and intestine. Small pieces of tissues from visceral organs were fixed in 10% neutral buffered formalin and histological sections were stained with haematoxylin and eosin (H&E). Photomicrography was done using Leica - WILD MPS 46 microcamera fitted to a Leitz - LABORLUX S microscope.

On necropsy of 17 grouper fish, two showed numerous brown to blackish nodules on the adipose tissues and visceral organs mainly on intestinal wall and pyloric caecae. These nodules of various sizes were raised slightly from the surface of the tissues and could be easily separated from tissues (Fig. 1). Microscopic examination of fresh squash preparations and Giemsa stained smears from infected tissues revealed large number of transparent oval shaped

spores measuring 4-6.5 x 2-2.5 μm with a single polar capsule containing polar filaments (Figs. 2 - 4) confirming the presence of microsporidia. The large posterior vacuole occupied broader posterior half. The detailed examination of fish for microbiological and parasitological investigations did not reveal major findings except mild infestation of gills with the monogenean belonging to the species *Benedinia epinepheli* Yamaguti, 1937.

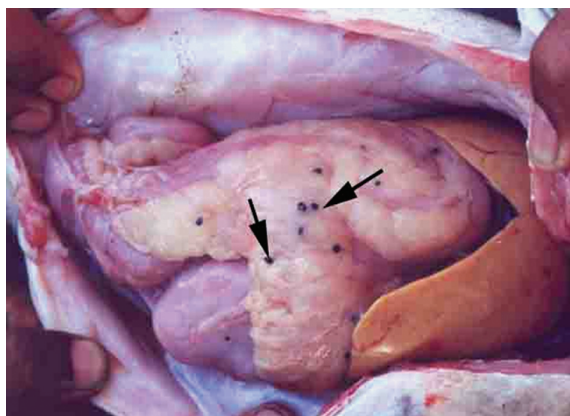


Fig. 1. Microsporidian (*Glugea* sp.) nodules (xenoma) in the visceral organs of *E. tauvina*

In histological sections, large numbers of spores were observed within the cysts. The cysts were surrounded by a dense connective tissue layer. The growth and proliferation of the microsporidian within the host cell results in the complete destruction of the cells. The developmental stages and mature spores gradually replace the cell contents until the host cell becomes a mere envelope containing the parasite. Host tissue is damaged by pressure atrophy, which elicits proliferation of the connective tissue, forming a layer around the parasite mass called xenoma. The cysts seem to be the overgrowth of the infected cells which induced multiplication of microsporidia. In histological sections of xenoma or cysts, the mature spores were observed in the core as well as in the sporoblast and immature spores in the periphery.

Microsporidians are a diverse group of parasites with almost 1200 species with confusion in species identity (Lom and Nilsen, 2003; Zhang, personal communication). However, Lom (2002) opined that fish microsporidian genera do not occur in other hosts. Definitive diagnosis of microsporidiosis is based primarily on life cycle and ultrastructural characteristics including size of developing and mature organisms, nuclear arrangements, number and alignment of polar filament coils, intracellular location, and modes of nuclear as well as cellular divisions (Dezfuli *et al.*, 2004). Due to species diversity, classification and determination of fish microsporidian species is very difficult. However, on the basis of morphology of the spore

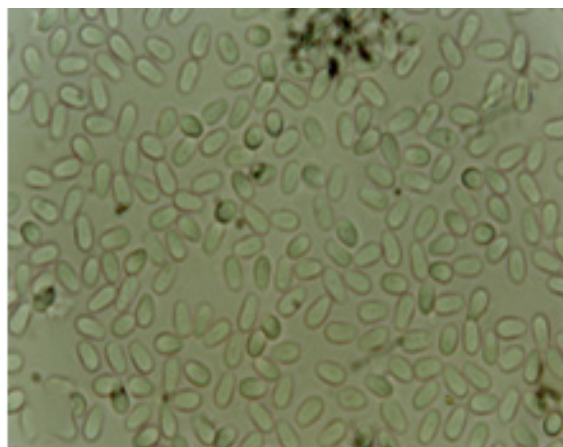


Fig. 2. Fresh spores of microsporidian (*Glugea* sp.) from *E. tauvina* (1000 X)

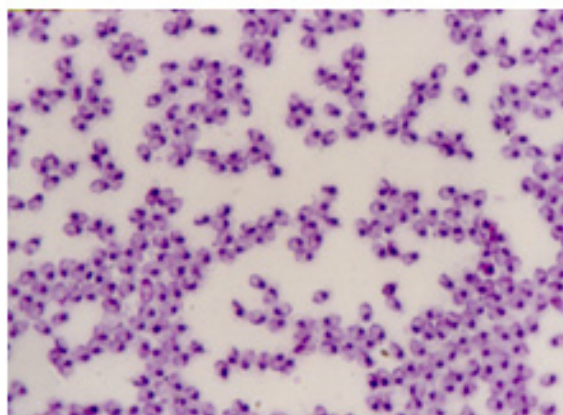


Fig. 3. Giemsa stained microsporidian (*Glugea* sp.) spore from *E. tauvina* (1000 X)

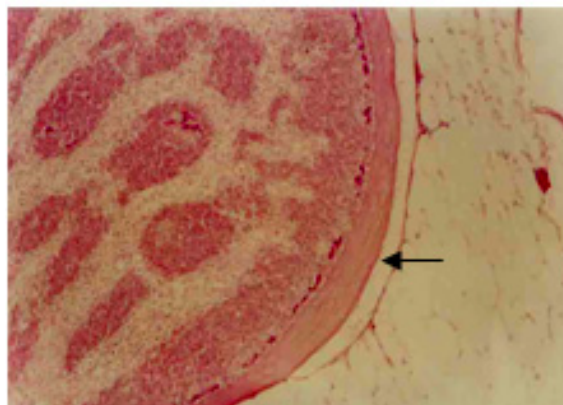


Fig. 4. Histological section showing *Glugea* sp. xenoma in the adipose tissues of *E. tauvina* (40 X) indicating the thick wall of host origin

on light microscopy and xenoma on histological studies, and also following the taxonomic key given by Lom and Dykova (1992), the microsporidian encountered in the present study was indistinguishable from *Glugea* sp. that forms large blackish xenoma with peripheral cytoplasmic

layer with sporophorous vesicle and the mature spores at the centre of the xenoma. Fish microsporidia are not very host specific (Lom and Dykova, 1992; Lom *et al.*, 1995; Nagasawa and Cruz-Lacierda, 2004; Payghan *et al.*, 2009). Two new species of *Glugea*, viz. *G. epinephelus* and *G. epinephelusis* were reported from marine fish *Epinephelus akaara* in China (Wu *et al.*, 2005; Zhang *et al.*, 2004, 2005). Mortality due to *Glugea epinephelus* infections, which produces black coloured xenoma in the abdominal cavity was reported by Wu *et al.* (2005) in cultured grouper (*E. akaara*) in China. This is the first report of microsporidia in groupers.

Acknowledgements

The authors are thankful to the Director, Central Institute of Brackishwater Aquaculture, Chennai for providing facilities.

References

- Casal, G., Matos, E., Leonor Teles-Grilo, M. and Azevedo, C. 2009. Morphological and genetical description of *Loma psittaca* sp. n. isolated from the Amazonian fish species *Colomesus psittacus*. *Parasitol. Res.*, 105: 1261-1271.
- Dezfuli, B. S., Giari, L., Simoni, E., Shinn, A. P. and Bosi, G. 2004. Immunohistochemistry, histopathology and ultrastructure of *Gasterosteus aculeatus* tissues infected with *Glugea anomala*. *Dis. Aquat. Org.*, 58: 193-202.
- Lom, J. 2002. A catalogue of described genera and species of microsporidians parasitic in fish. *Syst. Parasitol.*, 53: 81-99.
- Lom, J. and Dykova, I. 1992. *Protozoan parasites of fishes*. Elsevier Science Publishers, Amsterdam, The Netherlands, p. 125-157.
- Lom, J. and Nilsen, F. 2003. Fish microsporidia: fine structural diversity and phylogeny. *Int. J. Parasitol.*, 33: 107-127.
- Lom, J., Noga, E. J. and Dykova, I. 1995. Occurrence of a microsporean with characteristics of *Glugea anomala* in ornamental fish of the family Cyprinodontidae. *Dis. Aquat. Org.*, 21: 239-242.
- Nagasawa, K. and Cruz-Lacierda, E. R. 2004. *Diseases of cultured groupers*. Southeast Asian Fisheries Development Center, Aquaculture Department, Iloilo, Philippines, 81 pp.
- Payghan, R., Nabavi, L., Jamshidi, K. and Akbari, S. 2009. Microsporidian infection in lizard fish, *Saurida undosquamis* of Persian Gulf. *Iranian J. Vet. Res.*, 10: 180-185.
- Wu, H. B., Wu, Y. S. and Wu, Z. H. 2005. Occurrence of a new microsporidium in the abdominal cavity of *Epinephelus akaara*. *Acta Hydrobiol. Sin.*, 29: 150-154.
- Zhang, J. Y., Wu, Y. S., Lu, Y. S. and Wang, J. G. 2004. Advance in research of fish microsporidia. *Acta Hydrobiol. Sin.*, 28: 563-568.
- Zhang, J. Y., Wu, Y. S., Wu, H. B., Wang, J. G., Li, A. H. and Li, M. 2005. Humoral immune responses of the grouper *Epinephelus akaara* against the microsporidium *Glugea epinephelusis*. *Dis. Aquat. Org.*, 64: 121-126.

Date of Receipt : 02.06.2010

Date of Acceptance : 29.07.2011