

ISSN 0116-6514



**Asian  
Fisheries  
Science**

The Journal of the  
Asian Fisheries Society

Volume 12 No. 1  
May 1999

# Evidence of a Bacilliform Virus Causing Outbreaks of Whitespot Disease in *Penaeus monodon* H. Milne Edwards in India

A. SEN<sup>1</sup>, I.S. BRIGHT SINGH\*<sup>1</sup>, R. RENGARAJAN<sup>2</sup>, R. PHILIP<sup>1</sup>, G.S. KUMAR and A. SEN<sup>3</sup>

<sup>1</sup>Environmental Microbiology Laboratory  
School of Environmental Studies  
(School of Marine Sciences)  
Cochin University of Science and Technology  
Cochin 682 016, India

<sup>2</sup>Electron Microscopy Lab  
Central Marine Fisheries Research Institute  
Cochin 682 035, India

<sup>3</sup>Department of Veterinary Microbiology  
University of Agricultural Sciences  
Bangalore 560 024, India

## Abstract

Whitespot virus could be experimentally transmitted from infected *Penaeus monodon* to *P. indicus* and repeatedly passed on through several batches of apparently healthy *P. indicus*. During these passages, white spots first disappeared before subsequently reappearing. Electron microscopic studies revealed the presence of oblong-shaped, fully-assembled virus towards the periphery and virus in paracrystalline arrays towards the center of the hypertrophied nuclei. The virus isolated here is referred to as whitespot syndrome baculovirus (WSBV) until more is known of its antigenic and genomic relatedness to isolates from other countries.

## Introduction

The shrimp industry in Asia has been witnessing a pan-Asian epidemic of the whitespot disease (WSD) since 1993. First reported in Japan, the gross signs of the disease include white spots 1 to 2mm in diameter embedded in the cuticular underside and a general reddish discoloration of the body. The disease was associated with a bacilliform virus (the rod-shaped virus of the *P. japonicus* or RV-PJ) by Inouye *et al.* (1994) and Takahashi *et al.* (1994). Epidemiological investigations tracked the source of the virus to a batch of infected shrimp

---

\*Corresponding author.

from China (Nakano *et al.* 1994; Takahashi *et al.* 1994). Subsequent outbreaks were reported in Taiwan (Chen and Kou 1994) and southern Thailand (Asian Shrimp Culture Council 1994; Kasornchandra *et al.* 1994). The whitespot disease is caused by a single virus or closely-related variants that are non-occluded, enveloped, pleomorphic bacilliform virus with ds-DNA approximately 168 kbp long. The virus has a wide tissue tropism, infecting tissues of ectodermal and mesodermal origin and has a wide host range (Lo *et al.* 1996b). It is also extremely virulent, causing typical cumulative mortalities of 80 to 100% within 3-7 days at the onset of clinical signs (Chen and Kou 1994; Chou *et al.* 1995; Peng *et al.* 1995; Wang *et al.* 1995; Durand *et al.* 1996; Lo *et al.* 1996a; Wongteerasupaya *et al.* 1995). Aiming at a quick method of diagnosis, Lo *et al.* 1996a published a primer for the PCR-based detection of the virus. DNA probes were developed by other workers as well (Chang *et al.* 1996; Lo *et al.* 1996b; Takahashi *et al.* 1996; Wongteerasupaya *et al.* 1996). In India, a histopathological and bacteriological study of whitespot syndrome in *P. monodon* was made by Karunasagar *et al.* (1997) and vertical transmission of virus was demonstrated by Mohan *et al.* (1997). Ninawae (1997) gave an account of the devastation caused by whitespot disease on Indian prawn farms. The present paper deals with the experimental transmission of the virus to *P. indicus* and its repeated passages, and an electron microscopic demonstration of the virus in gill tissue of infected *P. monodon*. This has not been attempted in earlier studies in India.

## Materials and Methods

A batch of sub-adult tiger prawn *P. monodon* infected in a severe outbreak of WSD at a semi-intensive culture system of the Kerala Aquaculture Development Agency's Model Shrimp Farm in December 1995 was used for the present study. The animals (average body weight 3.5g) were stored at -20°C in a deep freezer until processed.

For virus extraction, the whole animal was used since the whitespot virus has been reported to have a wide tropism that included ectodermal and mesodermal tissues (Wongteerasupaya *et al.* 1995). For virus extraction, two to three animals showing characteristic white spots were retrieved from -20°C and thawed to room temperature (28±2°C). Tissues were minced and homogenized using sterile glass wool in a mortar using Dulbecco's Phosphate Buffered Saline (PBS, pH 7.0) to give a 1:10 (w/v) tissue suspension. After clarifying the tissue homogenate by centrifugation at 1,000 g for 10 minutes, the supernatant was collected and spun down at 10,000 g (4°C) for 30 minutes. It was then collected aseptically and stored as 2 ml aliquots of crude virus suspension at -20°C.

Suspensions were assayed for the presence of infective virus by injecting 0.01 ml of crude virus preparation intramuscularly into the last abdominal segment beneath the telson spine. For this, sub-adult *P. indicus* (5-8 g b.w) quarantined for not less than three days were used. *P. indicus* was used due to its easy availability and high susceptibility to the disease in field outbreaks.

Animals were maintained in 50-l FRP tanks filled with 20ppt filtered aged seawater and fed with autoclaved clam meat. As controls, animals maintained under identical conditions were inoculated with 0.01 ml clarified tissue suspension derived from apparently healthy animals. The inocula were tested for sterility by streaking out on nutrient agar plates. On developing clinical manifestations of the disease, test animals were used for virus extraction and the virus was subsequently passed through 12 batches of prawns over a period of 525 days in order to prove the Rivers Postulates (Rivers 1937). All shrimps that died during the infectivity trials were examined for gross manifestations of the disease, especially for the presence of spots on the carapace, by observing them under a stereomicroscope (Carl Zeiss, Germany).

To demonstrate the presence of virus in the infected animals, gills were removed from fresh animals and fixed in 2.5% glutaraldehyde overnight and post-fixed in osmium tetroxide for 2h at 4°C. The tissue was subsequently dehydrated in graded acetone (from 30% to absolute). After clearing in toluene and infiltration with toluene plus spurr medium at different proportions, embedding was done in a spurr low viscosity embedding medium (Polysciences Inc., USA). After polymerization at 70°C overnight, blocks were ultra thinly sectioned (Novotome, LKB) and sections mounted on 300 mesh size copper grids (SPI, USA). Sections were positively stained with uranyl acetate and lead citrate. Stained sections were observed under a transmission electron microscope (H 600, Hitachi Ltd, Japan).

## Results

The animals appeared to feed normally during the initial period post inoculation; roughly two days later, there was a total cessation of feed consumption. In most cases, shrimps were found swimming erratically and surfacing frequently approximately 12h before death. An hour before death, the animals were moribund and mortalities were uniformly 100% (cumulatively) within a group by the 5th day post inoculation.

All animals initially used for virus extraction were the ones with the most characteristic whitespots. Nevertheless, during subsequent passages, there were instances when whitespots disappeared among a given group of animals (46% out of 55 animals inoculated in 12 batches) while still registering 100% cumulative mortality. However, on inoculating the extract from such animals into new batches of shrimps, the clinical sign remanifested itself. During the trials, a large proportion of the dead animals also exhibited a characteristic reddening of the entire body. In a separate trial, on inoculating the virus suspension into the rearing water (0.5ml virus per 10-l water), it took 35 days for the appearance of clinical signs followed by subsequent mortality.

Gills of infected animals showed the presence of virus particles that were oblong-shaped, rounded at the ends and measuring approximately  $224 \pm 21$  nm x  $100 \pm 13$  nm when stained positively (Fig. 1 and Table 1). Infected cells revealed hypertrophied nuclei with marginated chromatin and paracrystalline arrays of virus (Figs. 2 and 3).

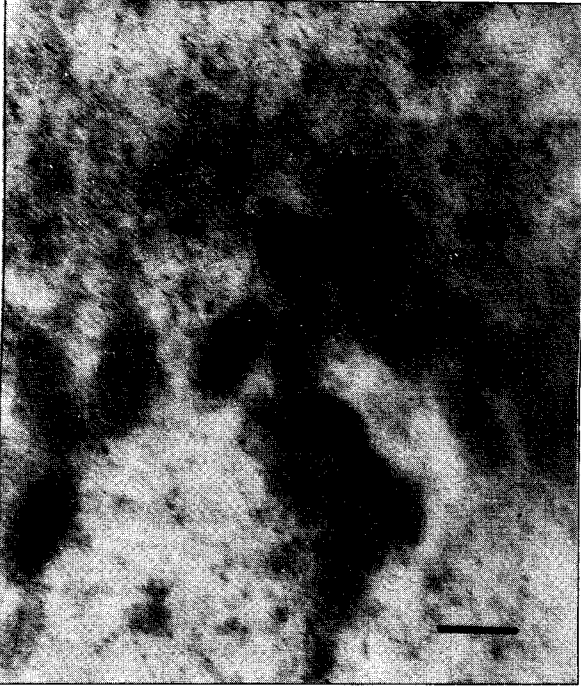

Fig. 1. Complete viral particles in the gill nucleus. Note the oblong-shaped, rounded and segmented appearance of the capsids (stained with uranyl acetate and lead citrate). Scale bar = 100 nm.

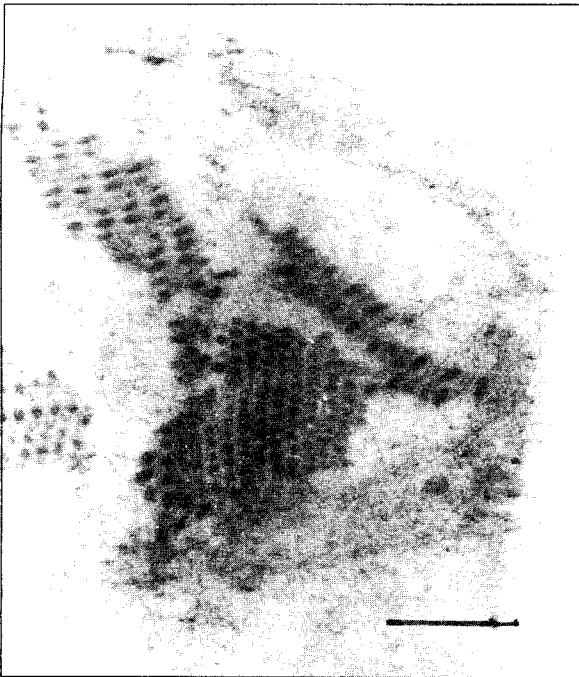


Fig. 2. Paracrystalline array of viral particles in the process of assembly within a hypertrophied nucleus. Scale bar = 1 $\mu$ m.

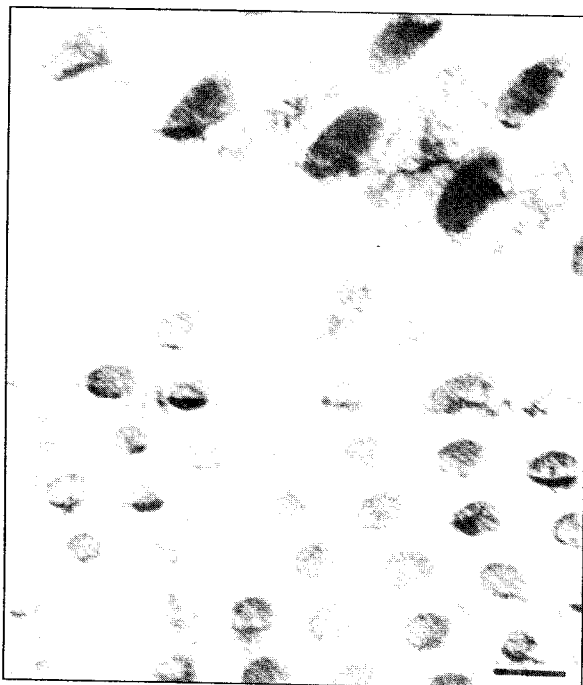


Fig. 3. Higher magnification of paracrystalline array of the viral particles showing both empty and full viruses. Scale bar = 100 nm.

Table 1. Comparison of size measurements of the virus in tissue sections with earlier reports.

Description	Present observations	Wongteerasupaya et al. 1995	Durand et al. 1996	Chou et al. 1995	Wang et al. 1995
Virus in tissue sections					
1. Full Virion (Length)	200-260 224±21 (x=10)	292±29	350; 400#	330±20	250-380
2. Full virion (Width)	80-20 100±15 (x=10)	111±8	130; 120#	87±7	70-150

Fully assembled capsids within the nucleus.

# Size of unique particles with cross-hatched appearance.

## Discussion

The characteristic signs observed such as the white inclusions of various sizes embedded in the carapace during the latter stage of the disease and reddening of the body are identical to accounts given in other studies (Wongteerasupaya *et al.* 1995; Lightner 1996; Nakano *et al.* 1994; Chou *et al.* 1995; Wongteerasupaya *et al.* 1996; Wang *et al.* 1995).

Although the appearance of whitespots is considered a clinical sign of this disease, the disappearance and reappearance of whitespots during virus passage evoke suspicion on its reliability as a sign of viral replication. Similarly, reddening of the body is an inconsistent indicator of viral involvement. The size of

the virus by TEM matches with that reported by Wongteerasupaya *et al.* (1995) and Wang *et al.* (1995). The TEM sections revealed paracrystalline arrays of viral capsids towards the center of the hypertrophied nuclei, an observation hitherto unreported for this virus. Virus in thin sections were pleiomorphic as reported earlier (Wang *et al.* 1995).

The virus responsible for WSD is currently known by several names such as systemic ectodermal mesodermal baculovirus (SEMBV) (Wongteerasupaya *et al.* 1995), whitespot syndrome baculovirus (WSBV) (Lo *et al.* 1996a), and rod-shaped virus of *P. japonicus* (RV-PJ) (Takahashi *et al.* 1996). Of these, the name WSBV, as pointed out by Lightner (1996), is the most suitable. Even though there have been changes in the taxonomy of baculoviruses by the International Committee for Taxonomy of Viruses (Murphy *et al.* 1995), the virus isolated here shall be referred to as whitespot syndrome baculovirus (WSBV) until more is known of its antigenic and genomic relatedness to other isolates.

### Acknowledgments

The authors wish to thank Dr. M. Devaraj, Director, Central Marine Fisheries Research Institute, for providing electron microscopy facilities required for this work. We acknowledge the able technical assistance of Mr. Ayyappan Pillai in the TEM work. We are also grateful to Dr. A.K. Sen for his valuable comments and suggestions.

### References

- Asian Shrimp Culture Council. 1994. SEMBV- an emerging threat to cultured shrimp in Asia. *Asian Shrimp News* 20:2-3
- Chen, S.N. and G.H. Kou. 1994. Viral infection and mass mortality of cultured shrimps in Taiwan. Abstracts, International Symposium on Biotechnology Applications in Aquaculture. 5-10 December 1994. Taipei, Taiwan, Asian Fisheries Society, p. A2.
- Chang, P.S., C.F. Lo, Y.C. Wang and G.H. Kou. 1996. Identification of whitespot syndrome associated baculovirus (WSBV) target organs in shrimp, *Penaeus monodon* by in situ hybridization. *Diseases of Aquatic Organism* 27:131-139.
- Chou, H.Y., C.Y. Huang, C.H. Wang, C.H. Chiang, and C.F. Lo. 1995. Pathogenicity of a baculovirus infection causing whitespot syndrome in cultured penaeid shrimp in Taiwan. *Diseases in Aquatic Organisms* 23:165-173
- Durand, S., D.V. Lightner, L.M. Numan, R.M. Redman, J. Mari and J.R. Bonami. 1996. Application of gene probes as diagnostic tools for white spot baculovirus (WSBV) of penaeid shrimp. *Diseases of Aquatic Organisms* 27:59-66
- Inouye, K., S. Miwa, N. Oseko, H. Nakano, T. Kimura, K. Momoyama and M. Hiroka. 1994. Mass mortality of cultured Kuruma shrimp *Penaeus japonicus* in Japan in 1993: electron microscopic evidence of the causative virus. *Fish Pathology* 29:149-158
- Karunasagar, I and S.K. Otta. 1997. Histopathological study of White Spot Syndrome of *Penaeus monodon* along the West Coast of India. *Aquaculture* 153:9-13
- Kasornchandra, J., S. Boonyaratpalin and K. Supamattaya. 1994. Electron microscopic observation on the replication of yellow head baculovirus in lymphoid organ of *Penaeus monodon*. Dept of Fisheries, Bangkok, Technical Paper No. 2:1-11.
- Killington, R.A and K.L. Powell. 1991. Growth and purification of herpes viruses. In: *Virology - a practical approach* (ed E.W.J. Mahy), pp. 234-240, IRL Press, Oxford.
- Lightner, D.V., Editor. 1996. A handbook of pathology and diagnostic procedures for disease of penaeid shrimp. World Aquaculture Society, Baton Rouge, LO.

- Lo, C.F., J.H. Leu, C.H. Ho, C.H. Chen, S.P. Peng, Y.T. Chen, C.M. Chou, P.Y. Yeh, C.J. Huang, H.Y. Chou, C.H. Wang and G.H. Kou. 1996a. Detection of baculovirus associated with white spot syndrome (WSBV) in penaeid shrimp using polymerase chain reaction. *Diseases of Aquatic Organisms* 25:133-141
- Lo, C.F., C.H. Ho, C.H. Peng, C.H. Chen, H.C. Hsu, Y.L. Chiu, C.F. Chang, K.F. Liu, M.S. Su, C.H. Wang and G.H. Kou. 1996b. Whitespot syndrome baculovirus (WSBV) detected in cultured and captured shrimp, crab and other arthropods. *Diseases of Aquatic Organisms* 27:215-225
- Mohan, C.V., P.M. Sudha, K.M. Shankar and A. Hegde. 1997. Vertical transmission of white spot baculovirus in shrimps - a possibility? *Current Science* 73:109-110
- Murphy, F.A., C.M. Fauquet, D.H.L. Bishop, S.A. Gabrial, A.W. Jarvis, G.P. Martelli and M.D. Summers. 1995. Classification and nomenclature of viruses. *Archives of Virology (Suppl)* 10:1-586
- Nakano, H, H. Koube, S. Umezawa, K. Momoyama, H. Hiraoka, K. Inouye and N. Oseko. 1994. Mass mortalities of cultured kuruma shrimp, *Penaeus japonicus* in Japan in 1993: Epizootiological survey and infection trials. *Gyobo Kenkyu (Fish Pathology)* 29:135-139.
- Ninawae, A.S. 1997. How white spot disease devastated Indian fish farms. *Fish Farming International* 24(3):12-13.
- Peng, S.E, C.H. Chen, C.F. Lo and G.H. Kou. 1995. Detection of whitespot syndrome associated non-occluded baculovirus in penaeid shrimps. Abstracts, Seventh International Conference on Diseases of Fish and Shellfish, 10-15 September 1995. Palma de Mallorca, Spain, p. 8.
- Rivers T.M. 1937. Viruses and Koch's postulates. *Journal of Bacteriology* 33:1-12.
- Takahashi, Y., T. Itami, M. Kondo, M. Maeda, R. Fujii, S. Tomonaga, K. Supamattaya and S. Boonyaratpalin. 1994. Elecrom microscopic evidence of bacilliform virus infection in kuruma shrimp (*Penaeus japonicus*). *Fish Pathology* 29:121-125.
- Takahashi, Y., T. Itami, M. Maeda, N. Suzuki, J. Kasornchandra, K. Supamattaya, R. Khongpradit, S. Boonyaratpalin, M. Kondo, K. Kawai, R. Kusuda, I. Hirono and T. Aoki. 1996. Polymerase chain reaction (PCR) amplification of bacilliform virus (PV-PJ) DNA in *Penaeus japonicus* Bate and systemic ectodermal mesodermal baculovirus (SEMBV) DNA in *Penaeus monodon* Fabricius. *Journal of Fish Diseases* 19:399-403.
- Wang, C.H, C.F. Lo, J.H. Leu, C.M. Chou, P.Y. Yeh, H.Y. Chou, M.C. Tung, C.F. Chang, M.S. Su and G.H. Kou. 1995. Purification and genomic analysis of baculovirus associated with white spot syndrome (WSBV) of *Penaeus monodon*. *Diseases of Aquatic Organisms* 23:239-242.
- Wongteerasupaya, C, J.E. Vickers, S. Sriurairatna, G.L. Nash, A. Akrajamorn, V. Boonsaeng, S. Panyim, A. Tassanakajon, B. Withyachumnamkul and T.W. Flegel. 1995. A non-occluded systemic baculovirus that occurs in cells of ectodermal and mesodermal origin and causes high mortality in the black tiger prawn *Penaeus monodon*. *Diseases of Aquatic Organisms* 21:69-77.
- Wongteerasupaya, C, S. Wongwisansri, V. Boonsaeng, S. Panyim, P. Pratanpipat, G.L. Nash, B. Withyachumnamkul and T.W. Flegel. 1996. DNA fragment of *Penaeus monodon* baculovirus gives positive in situ hybridization with white spot viral infections in six penaeid shrimp species. *Aquaculture* 143:23-32.