

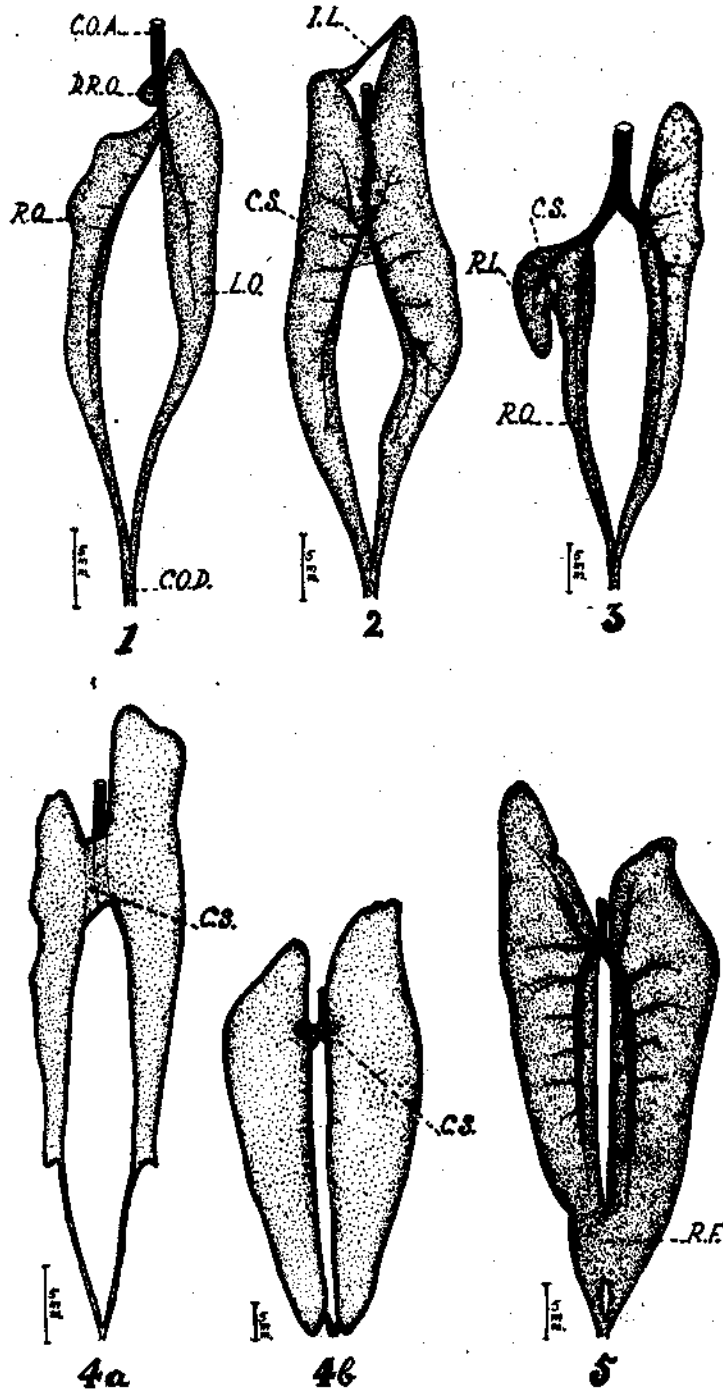
**FURTHER INSTANCES OF GONADIAL PECULIARITIES IN
*SARDINELLA LONGICEPS VALENCIENNES***

SINCE reporting some gonadial abnormalities in the Indian oil sardine, *Sardinella longiceps* in an earlier account (Bensam, 1964), a few more instances from the same locality, Cannanore, have come to notice and are briefly described in the present note.

1. *Female with divided right gonad* (maturity stage II)—Fig. 1. Here the right gonad is divided into two components, an anterior semi-circular one measuring 2 mm. long and 2 mm. wide at the widest region, with its base attached to the common ovarian artery; and a lower main portion supplied with the right ovarian artery and its posterior end continued as its oviduct like in normal cases. In the unusual ovary described by Dhulkhed (1965) both the right and the left gonads are divided into anterior and posterior lobes, which is different from the condition observed in the present case.

2. *Female with intergonadial loop* (stage II+)—Fig. 2. In this case the two ovaries are connected with each other anteriorly by a transverse loop measuring 8 mm. across and about 1 mm. in width. Minute ova inside the lumen of the loop are recognisable.

3. *Female with bilobed right gonad* (stage II)—Fig. 3. The right gonad in this specimen is divided into a large main lobe, supplied with a branch of the right ovarian artery and its hind end forming the oviduct; and a smaller lobe lying on the right side of the former supplied with another branch of the right ovarian artery. The two lobes are attached with each other by two strands of semitransparent connective tissue. The lumens of the two lobes are continuous with each other only along their anterior aspects.



FIGS. 1-5: Ventral views of the abnormal gonads of *Sardinella longiceps*. Fig. 1 divided right ovary; Fig. 2 interovarian loop; Fig. 3 bilobed right ovary; Fig. 4a intertesticular connective tissue band; Fig. 4b intertesticular connective tissue bundle; Fig. 5 interovarian fusion. C.O.A. common gonadal artery; C.O.D. common gonoduct; C.S. connective tissue; D.R.O. divided right gonad; I.L. intergonadal loop; L.O. left gonad; R.F. region of fusion; R.L. right gonadal lobe; R.O. right gonad.

4. *Males with intergonadal connective tissue* (stages II+) Figs. 4a and 4b. Two male specimens having this peculiarity were collected. In one case (fig. 4a), the connective tissue is in the form of a flattened semitransparent band, partially masking the testicular artery from the ventral side, while in the second specimen (Fig. 4b), it is in the form of a bundle of semitransparent strands.

5. *Female with intergonadal fusion* (stage IV) Fig. 5. This case differs from a condition reported earlier (Bensam, *l.c.*), in that the intestine is not involved in the fusion of the ovaries posteriorly.

*Central Marine Fisheries Research Institute,
Mandapam Camp.*

P. BENSAM**

REFERENCES

- BENSAM, P. 1964. *J. Mar. biol. Ass. India*, 6 (1) : 135-142.
DHULKHED, M. H. 1965. *Ibid.*, 7 (1) : 210-212.