

Note on an abnormal specimen of golden snapper

Swatipriyanka Sen Dash, K. Mohammed Koya, Gyanranjan Dash, Sangita A. Bharadiya and Jayshree Gohel

Veraval Regional Centre of ICAR-Central Marine Fisheries Research Institute, Veraval

Morphological deformities or abnormalities are well documented in many fishes from several parts of the world, including Indian waters. Several reasons such as genetic aberrations, pollution, environmental stress, accidental injury during the growing period of the fish etc. have been attributed to the presence of abnormalities in fishes. Deformity

head length was slightly shorter than body depth. The dorsal fin was continuous without any incision. The caudal peduncle along with fin was completely absent in the specimen. In the absence of caudal peduncle, both the dorsal and anal fins converged together at the posterior end of the body. The bases of both dorsal and anal fins were with scales.




Fig. 1. Normal (A) and abnormal (B) *Lutjanus johnii*

in the lower jaw of Malabar red snapper, *Lutjanus argentimaculatus* due to the dislocation of the hyoid bones (Sethi, 2012 *Marine Fisheries Information Service T&E Ser.*, 213:14) has been reported. In the present note, an abnormal specimen of *Lutjanus johnii* (Bloch, 1792) (Fig. 1) collected from by-catch of a single day trawler that was operating in Gujarat waters is described. In this specimen, the posterior part of the body behind the dorsal and anal fins was completely absent as compared to a normal fish. Morphometric and meristic data of the abnormal specimen were recorded and the specimen preserved in the museum for future reference (Fig. 1). A radiograph was also taken to study the osteological features (Fig. 2).

The fish identified as *Lutjanus johnii* was moderately deep, with convex head profile. The

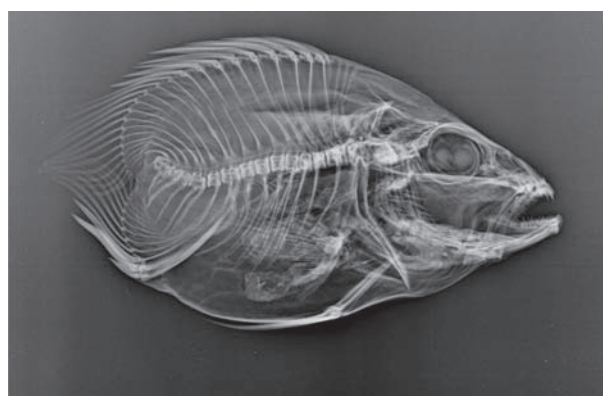


Fig. 2. Radiograph of abnormal specimen

Longitudinal rows of scales, on both sides of the body, above and below the lateral line had a distinct brownish/dark spot which was more prominent in the dorsal portion of the body. The body was bronze

in colour while all the fins were yellowish and a large black spot was present above the lateral line. From the radiograph it was evident that only 18 (10+8) vertebrae were present in this abnormal specimen, while the lutjanids normally have 24 (10+14) vertebrae (Nelson, 2006 *Fishes of the World*, John Wiley & Sons). The vertebral column of the deformed specimen was not normal in shape and alignment with the posterior vertebrae was totally absent. The defect in the vertebral column of the present specimen could be an anomaly in development due to some congenital disorder rather than due to some predator attack. In the case of

survivors of predator attacks, signs of regeneration such as scar tissue, missing scales on the skin, missing or regenerating appendages can be seen which was not observed in the present specimen. Any anomaly in the caudal fin will impair the flexibility of the tail, which can hinder the performance of the fish not only during capturing its prey but also while escaping from its predators. The present specimen, despite being deprived of entire caudal region showed no sign of emaciation or predated upon. The fish is therefore, believed to have suffered mortality due to fishing, along with other fishes during the trawling operation.