

HISTOLOGY OF HEMATOPOIETIC TISSUES IN THE INDIAN WHITE PRAWN

Penaeus indicus (H.Milne Edwards)

Dissertation submitted by

ASHOK REDDY G.

LIBRARY
13/07/99
Central Marine Fisheries Research Institute
Kochi - 682 014
No. 427/2000
D 243

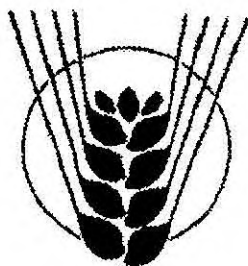
In partial fulfillment for the degree of

MASTER OF FISHERIES SCIENCE (MARICULTURE)

of the

Central Institute of Fisheries Education

(Deemed University)



ICAR

JULY 1999

LIBRARY OF THE CENTRAL MARINE FISHERIES RESEARCH INSTITUTE
Kochi - 682 014
No. 427/2000
D 243

POST GRADUATE PROGRAMME IN MARICULTURE

Central Marine Fisheries Research Institute

Kochi - 682 014

Dedicated to

My beloved parents

CONTENTS

NAME	PAGE NO.
CERTIFICATE	I
DECLARATION	II
ACKNOWLEDGEMENT	III-IV
ABSTRACT IN HINDI	V
PREFACE	1-2
INTRODUCTION	3-6
REVIEW OF LITERATURE	7-15
MATERIALS AND METHODS	16-18
RESULT	19-21
FIGURES	22-30
DISCUSSION	31-35
SUMMARY	36-37
REFERENCES	38-47

CERTIFICATE

Certified that the dissertation entitled "Histology of Hematopoietic tissues in the Indian white prawn *Penaeus indicus* (H.Milne Edwards)" is a bonafide record of work done by Mr. Ashok Reddy G. under our guidance at the Central Marine Fisheries Research Institute during the tenure of his M.F.Sc. (Mariculture) programme of 1997-1999 and that it has not previously formed the basis for the award of any other degree, diploma or other similar titles or for any publication.



Dr. K.C. George,
Senior Scientist,
CMFRI, Kochi,
Major Advisor, Advisory Committee.



Dr. Mary K. Manisseri,
Senior Scientist,
CMFRI, Kochi,
Member, Advisory Committee.




Dr. N.K. Sanil,
Scientist (Sr. Scale),
CMFRI, Kochi,
Member, Advisory Committee.

DECLARATION

I hereby declare that this thesis entitled " Histology of Hematopoietic tissues in the Indian white prawn *Penaeus indicus* (H.Milne Edwards)" is based on my own research work and has not previously formed the basis for the award of any degree, diploma, associateship, fellowship or any other similar titles or recognition.

Kochi – 682 014


(ASHOK REDDY G.)

ACKNOWLEDGEMENT

I acknowledge my deep sense of gratitude to Dr. K.C. George, Guide, Senior Scientist, CMFRI for his guidance, constant encouragement, and supervising the work, without which this work would not have been possible. I am deeply grateful to Dr. N.K. Sanil, Co-guide, Scientist, CMFRI for his guidance and valuable help during the course of my work.

I would like to extend my sincere thanks to Dr. M. Devaraj, Former Director, and Dr. V.N. Pillai, Director of CMFRI, for having permitted me to avail the facilities at the Institute, during the course of this study. I take this chance to thank Dr.C.Suseelan, Senior Scientist and Officer-in-charge, PGPM, CMFRI, for his help and the facilities provided.

I am much obliged to Dr.Mary K.Manisseri, Co-guide, Senior Scientist; Dr.P.C.Thomas, Senior Scientist; Dr.V.Chandrika, Senior Scientist; Dr.Sudhakara Rao, Principal Scientist and Head of CFD, CMFRI for their help and advise.

I must also wish to express my thanks to Dr.K.Mohan Das, Director, CUSAT for permitted me to take photomicrographs.

I acknowledge with thanks the help rendered by Shri. P.M.Aboobecker and Shri. Nandakumar Rao.

I am greatly indebted to my Seniors Mrs. Jijo, Mrs. Nisha, Miss. Jasmin for their affection and help rendered during the course of this study. I am deeply grateful to my classmates, Miss. Radhika, Shri. Sunil, Shri. Prabhakar, Shri. Sandeep, Shri. Babu, Shri. Binu, Shri. Unni and Miss. Madhavi for their constant help to complete my work successfully.

I would like to express my profound gratitude to Dr. Gary G. Martin, Occidental College, California, USA for his kind help in sending references.

Finally, I wish to express my thanks to ICAR for having awarded me Junior Research Fellowship during the tenure of which the present study was carried out.

साराँश

इंडिकस झींग (एच. मिलने एडवारड्स) के रक्तोत्पादक ऊतकों के ऊतकीय विश्लेषण इस अध्ययन में किया गया है। रक्तोत्पादक ऊतकों को ढूँढ निकालने को जन्तु के शरीर को क्रमिक रूप से काटकर जाँच किया। अध्ययन में हेपाटोपान्क्रियास व उदर के पृष्ठ तल में, पहले जम्भपाद युग्मों के नीचे, पार्श्व धमनीय वाहिका के चारों और श्रृंगिक ग्रन्थि भाग में रक्तोत्पादक ऊतक दिखाए पडे। ऊतकों का विश्लेषणात्मक अध्ययन, हीमोटाक्सिलिन-इयोसिन, मासन्स-ट्राइक्रोम और वानगीसन स्टेइन के जरिए किया। आधिजठर भाग में ऊतक, गांधिका के रूप में रेशेदार संयोजी ऊतकों से घेरे हुए इकट्ठे हुए थे। प्रत्येक ग्रन्थिका में कई पालिका थे। अन्य भागों में रक्तोत्पादक ऊतक पालियों में लचीले संयोजी ऊतकों से घेरे हुए दिखाए पडे। स्तंभ कोशिका और विभेदक कोशिकाओं की संरचनात्मक अध्ययन भी किया गया।

PREFACE

PREFACE

Aquaculture industry is getting more attention all over the world because of its nature of providing food, export earnings, employment generation and upliftment of the socio-economic status of rural people.

Recently shrimp is in great demand in international markets. This demand can not be met by the fisheries. Hence there is a spurt in intensive aquaculture activities.

In India, shrimp aquaculture is shifting from semi-intensive to intensive type. High stocking densities in intensive aquaculture encourage the development and transmission of many diseases within cultured populations

The prevention and control of diseases are now considered to be the priority area of shrimp aquaculture for its development and sustainability. The intensification of shrimp production based on progress in zootechnology, occurred despite a lack of scientific knowledge about shrimp physiology. Within this field, research in immunology has been a subject of only minor interest, particularly when compared to other animals.

Shrimp immunology is a key element in the development of strategies for the control of diseases in shrimp aquaculture. Now serious investigations are progressing on the immune system of shrimp.

One of the primary requirement in understanding the immunology of any species is the knowledge on the origin, development, and maturation sequence of effector cells or hemocytes. In shrimps, host defense

mechanism is largely based on the activities of the blood cells or hemocytes. There is not much studies on the origin, development, and maturation sequence of hemocytes. we feel that it is essential to initiate studies on these aspects in the Indian white prawn *Penaeus indicus* which is extensively used as a candidate species for aquaculture in India. Hence the present study was initiated with a view to fill the vacuum in the knowledge of above area.

INTRODUCTION

INTRODUCTION

Crustaceans like other arthropods, have an open circulatory system. Hence, the blood has been termed 'hemolymph'. The hemolymph of crustaceans carries numerous non-pigmented cells called hemocytes. Since an open circulatory system is more susceptible to repeated intrusions from the surrounding environment, interest in hemocytes have been revived and enlarged because of their implication in wound repair and defense mechanisms.

The location of stem cells, the cell lineage, and the activities and fate of crustacean hemocytes, particularly those of decapods have been the subjects of numerous studies. In the literature, there are several synonymous terms for the hemocytes and for the hematopoietic tissue. In earlier papers, hematopoietic tissue was referred to as the lymphogenic, lymphocytogenic, leucopoietic, or globulinogenic tissue or organ (Cuenot 1893, 1904; Kollman 1908). Hemocytes have been called leukocytes or amoebocytes, and some authors devised complicated terminologies for various kinds of hemocytes. These terminologies were often based on supposed similarities to mammalian blood cells (George and Nichols, 1948).

Earlier attempts to classify crustacean hemocytes were based on morphological criteria such as cell size, shape and the presence or absence of cytoplasmic granules. Many workers have recognized three types of hemocytes based on purely morphological criteria. The hemocyte categories

were: hyaline, semigranular, and granular cells (Johnson 1980; Bauchau, 1981).

Some workers have developed a scheme for classifying decapod hemocytes that includes morphology, cytochemistry, antigenic characteristics, functional and Hemogram studies (Martin and Graves, 1985; Hose et al., 1987; Hose and Martin, 1989; Tsing et al., 1989; Hose et al., 1990; Hose et al., 1992; Karin Van de Braak and WPV van der Knaap, 1998).

The hemocytes of crustaceans are reported to participate in numerous physiological activities such as production of hemocyanin, ecdysis, carbohydrate transport and metabolism (Stang-Voss, 1971; Bauchau and Plaquet, 1973; Williams and Lutz, 1975). The defense reactions of crustacea which include wound repair, clotting of the hemolymph, phagocytosis, encapsulation, hardening of the cuticle and release of prophenoloxidase activating system (Fontaine and Lightner, 1973; Smith and Ratcliffe, 1980; White and Ratcliffe, 1982; Vacca and Fingerman, 1983; Hose et al., 1984; Durliat, 1985; White and Ratcliffe, 1985; Hose and Martin, 1989; Krol et al., 1989; Omori et al., 1990; Durliat, 1992; Soderhall and Cerenius, 1992).

Decapod hemocytes are produced within the specialized tissue called hematopoietic tissue. The location and architecture of the hematopoietic tissue vary greatly, between species. In decapods two patterns of organisation of hematopoietic tissue have been described: Lobular and nodular. Lobular hematopoietic tissue have been seen in crabs, crayfish and lobsters. The hematopoietic lobules are situated within a sheet of spongy

connective tissue overlying the stomach. The connective tissue layer in turn is covered by a thin intimal layer. Stem cells line the apical boarder of each lobule and maturing hemocytes migrate toward the hemal space. Young hemocytes are liberated into adjacent hemal spaces and then into the general circulation. (Ghiretti-Magaldi et al., 1977; Johnson, 1980; Martin et al., 1993; Chaga et al., 1995).

Nodular hematopoietic tissues has been found only in penaeid shrimps. This appear as paired epigastric nodules, which are composed of highly branched blood vessels, each with developing hemocytes forming a thickened wall. A hemopoietic artery branches from each of the ophthalmic arteries, just anterior to the heart. As the vessel approaches the *cardiac stomach*, it divides repeatedly to form a delta of progressively smaller tubules lying on the dorsal surface of the foregut (Oka, 1969; Martin et al., 1987).

However, the typical lobular hematopoietic tissue has been identified at the base of Maxillipedes of *Penaeus* (Bell and Lighner, 1988).

Bohm and Gersch (1983) and Bell and Lightner (1988) reported loose aggregations of hematopoietic tissue around the antennal artery of cray fish and penaeid shrimp respectively.

Since the major effector cells of defense system in crustaceans are hemocytes. The study of their origin will assist our understanding of crustacean immunology, hematology and physiology. Recently lot of interest is being generated in understanding the defense mechanisms of crustaceans

because with expansion of shrimp aquaculture there is an increased in problem of disease outbreaks.

The objectives of this study are,

- (1) To get a better in sight into hematopoietic system of Indian white prawn ***Penaeus indicus*** which is cultivated extensively.
- (2) To gain better understanding of the crustacean hematopoietic tissue and the origin of effector cells of crustacean immunity.

***REVIEW
OF
LITERATURE***

REVIEW OF LITERATURE

Hematopoietic tissue: The location of hematopoietic tissue was first described in *Palaemonetes varians* by Allen (1893) and subsequently in a variety of crustaceans (Cuenot, 1893, 1904). The hematopoietic organs were identified by the presence of dividing and maturing hemocytes in the hematopoietic tissue (Allen, 1983; Cuenot, 1904; Bruntz, 1907; Kollman, 1908).

In pagurid and caridean decapods, the hematopoietic tissue occurred next to or enveloped the ophthalmic artery, either at its anterior end or along its entire length (Cuenot 1893, 1904).

Miculicich (1905) described hemocyte forming nodules in the anterior part of the trunk of the parasitic copepod *Branchiella sp.*

Bruntz (1907, 1909) investigated the hematopoietic tissue not only in decapods, but in most of the other groups of higher crustaceans. In Eumalacostracans, the hematopoietic tissue was located in each group as follows. Isopoda (*Ligia, Oniscus, Asellus, Paragnathia*): bilaterally in one or both of the last thoracic segments and in the first abdominal segment. Amphipoda (*Talitrus, Gammarus, Protella*): bilaterally in the head. Stomatopoda (*Squilla*): along the surface of the ventral artery. Mysidacea (*Mysis*): On the surface of the cardiac stomach; and Cumacea (*Iphnioe*): bilaterally, in the fifth thoracic segment. The author has not located the hematopoietic tissue in the leptostracan *Nebalia geoffroyi* and suggested that this group depend on direct division of cells in the hemolymph.

Hematopoietic tissue was located bilaterally, at the base of each limb in the anostracans *Artemia salina* and *Branchipus schaefferi* (Lochhead and Lochhead, 1942). Debaisieux (1952) found hematopoietic tissue in the same position in the anostracan *Chirocephalus diaphanus*, but hematopoietic tissue was lacking in the branchiuran *Argulus foliaceus* (Debaisieux 1953).

Oka (1969) found a new lymphoid organ of prawn *Penaeus orientalis* in the epigastric region. Lymphocytes and lymphoid tissues were noticed in the newly found organ and reported that the leukopoietic organ can also be called as lymphoid organ.

Charmantier (1972) described the hematopoietic organ of crab *Pachygrapsus marmoratus*. It was formed of long modules surrounded by a conjunctive septum. Two types of cells were noticed in the hematopoietic organ: large stem cells with large nuclei present at the periphery of the nodules and round hyaline leukocytes with small round nuclei. Thickness of the organ, density of the nodules and mitotic index were studied. The thickness of the organ was maximal in D₃ molt stage.

Ghiretti-Magaldi et al., (1977) investigated the ultrastructure of hemocytes, hematopoietic organ and also observed the presence, origin and evolution of cyanoblasts and cyanocytes in the hematopoietic tissue of crab *Carcinus maenas*. The organ was composed of cup-shaped lymphatic-follicles located in the dorsal wall of the gizzard. The single follicles were lined by a basement membrane with one opening. Mitosis was observed in the

follicles. Differentiation of hemoblasts into hemocytes occurred in the follicles. The cells detached from the follicle through its open side.

Bazin (1979) conducted the cytological study on the hematopoietic organ of the crab *Carcinus maenas*. It was formed by nodules. Nodules were surrounded by a limiting layer which included collagenous filaments and basal lamina. Fibrocytes and semigranulous hemocytes were lined this limiting layer. These hemocytes were transformed in fibrocytes. Fibro-blast like cells, with well developed intercellular junctions were the first cell type. They were differentiated into mitotic cells. These mitotic cells were named as hemocytoblasts and they were stem cells for hyaline hemocytes.

Johnson (1980) have conducted investigations on the hematopoietic tissue of the blue crab *Callinectes sapidus* in intermolt, pre-and post molt animals. The tissue was situated in a sheet of spongy connective tissue. The connective tissue was joined to the epithelium of the cardiac stomach at intervals and hemal sinuses occurred on both sides of the connective tissue. The organ was arranged into lobules composed of stem cells and young hemocytes. In intermolt animals, each lobule was composed of a layer of hemocytes upto ten cells deep.

Bauchau (1981) investigated the structure of hematopoietic tissue of the crab *Eriocheir sinensis* and reported that tissue spreads extensively over the dorsal and lateral walls of the foregut. In each nodule, stem cells with large nuclei and hyaline cytoplasm underwent regular mitosis and produced small

hyaline daughter cells which left the body cavity and migrated into the general body circulation. The stem cells were called as hemoblasts.

Lightner and Redman (1982) found the hematopoietic tissue was located at the base of Maxillipedes during their investigation on the histopathology of aflatoxicosis in the marine shrimp *Penaeus stylirostris* and *P. vannamei*.

Bohm and Gersch (1983) have conducted studies on the cephalic gland situated in the antennal segment of cray fish *Orconectes limosus*. Topographical, histological and radioimmunological investigations of this gland demonstrated that this tissue was not an endocrine gland. It was a dorso-lateral part of the hematopoietic complex. This hematopoietic complex lay on the dorsal and lateral wall of the foregut. The hematopoietic complex was formed of nodules and frequently there were also expanded ridge like structures instead of nodules.

Martin et al. (1987) described the architecture and fine structure of the epigastric hematopoietic nodules of the ridgeback prawn *Sicyonia ingentis* at light and electron microscopic levels. The nodules consisted of a highly branched series of tubules that contained the maturing hemocytes within the connective tissue stroma. Four hemocyte categories were observed in the hematopoietic tissue.

Bell and Lightner (1988) have conducted the investigation on histology of penaeid shrimp *Penaeus stylirostris* and found the hematopoietic tissues located in epigastric region, at the base of maxillipedes, surrounding the lateral arterial vessel, and antennal gland region. The hematopoietic tissue

surrounding the lateral arterial vessel was quite extensive and covers large portion of vessel.

Martin et al., (1989) described the fine structure of major arteries of the shrimp *Sicyonia ingentis* and reported three vessel morphologies. The hematopoietic vessels that branch off the ophthalmic arteries displayed the third type of vessel wall morphology. The lumen of the vessel was lined by a very thin basal lamina, which completely encircled the endothelial cells. Internal to the endothelial cells there was a layer composed of hemocytes of various maturation stages embedded in a matrix of fibroblast like cells and collagen fibrils. The morphology of the vessel was same as that described for tubules of the epigastric hematopoietic tissues in the ridgeback prawn *Sicyonia ingentis*.

Martin et al., (1993) investigated the hematopoietic tissue in the american lobster *Homarus americanus* and reported that the tissue was covering the dorsal surface of the foregut and it was composed of loosely attached ovoid lobules containing stem cells and maturing hemocytes. Cross sections of the lobules were reported to contain between 6 and 40 hematopoietic cells. The mitotic index was ranged from 0.7% to 15.8% with a mean average of 5.1% in intermolt lobsters.

Chaga et al., (1995) investigated the hematopoietic tissue of the signal cray fish *Pacifastacus leniusculus* and reported that hematopoietic tissue covered the dorsal and dorso-lateral surface of the stomach. It was surrounded by a thin sheath of spongy connective tissue and was composed

of several types of hematopoietic cells, which were densely packed in lobules and were also present in interlobular spaces. Five types of hematopoietic cells were identified by means of differential interference contrast microscopy and electron microscopy.

Hematopoiesis: Early investigations on hematopoiesis in crustacea (Cuenot, 1893; Bruntz, 1907; Kollman, 1908) suggested that the circulating hemocytes of crustacea derived from a hematopoietic organ made by lymphocytogenic nodules located either around the ophthalmic artery or gizzard walls. These researchers have developed a single line of differentiation, with granulocytes arising from the hyaline hemocytes.

According to Kollman (1908) the hematopoietic nodules were formed by mesenchymal cells some of which become connective tissue and produced a supporting matrix while others evolved into various kinds of ameboid hemocytes after proliferation and detachment from the nodules.

Marrec (1944) reported that mitotic activity in hematopoietic tissue of crab *Carcinus maenas* was high during the intermolt period i.e. moltstage B and early C, and low immediately after molting (Stage A). The majority of hemocytes were released during the ecdysinal interval ie moltstages D through A.

Charmantier (1972) studied hematopoiesis during different stages of molting in the crab *Pachygrapsus marmoratus*. From molt stage A (exuviation) to molt stages C2 to C3 of the post molt, the thickness of the hematopoietic organ and the mitotic index were increased during the above mentioned

stages. The nodules with stem cells at molt stage A were filled with hyaline leukocytes. At molt stage C4 there was decrease in hematopoietic activity which was indicated by lowered mitotic index and smaller size of nodules. From premolt stages D0 to D3 (stages of premolt) activity was raised again. The thickness of the organ was maximal in D3 molt stage, and in this stage, there was an accumulation of formed leukocytes. The hyaline leukocytes formed in the stages of premolt were released in D3 before exuviation. The hemolymph was reported to contain numerous granular leukocytes in premolt stages. Probably from the differentiation of hyaline leukocytes which were liberated at post molt stages C2 to C3.

Ghiretti – Magaldi et al., (1977) noticed that the hematopoiesis in the crab *Carcinus maenas* occurred in the lymphocytogenic nodules of the gizzard walls. All blood cells were derived from a single cell line which proliferated in the nodules. The stem cells or hemoblasts differentiated into circulating hemocytes and into cyanoblasts, which were non-circulated blood cells. Their differentiation into cyanocytes was characterised by the synthesis and accumulation of hemocyanin. Four kinds of hemocytes were identified. One agranulated and three different granulated cell types.

Johnson (1980) described three types of stem cells in the hematopoietic tissue of the blue crab *Callinectes sapidus*. Each stem cell was present in different lobules. One cell had granular nuclei of 6 to 8µm diameters with distinct nucleoli, and densely basophilic, finely granular cytoplasm. The second type of stem cell had dense homogeneous nuclei with the same measurements of the first one. Mitotic figures were rare in areas of dense

homogenous nucleated cells. Third type had smaller homogeneous nuclei of about 5.5µm in diameter and lacked distinct nucleoli. Another type of nodule of about one to two cells depth was also mentioned and which possessed high mitotic activity.

The author has studied the hematopoiesis during different molt stages, and reported that the major release of hemocytes occurred during the ecdysial interval (molt stages D4 through A) and also mentioned the effect of stress on hematopoiesis.

Hose et al., (1984) studied the pathogenesis of *Fusarium solani* infections in the California brown shrimp, *Penaeus californiensis* and reported low mitotic activity of hematopoietic tissues of the penaeid shrimp. During infections, mitotic activity was doubled in the epigastric hematopoietic tissue.

Martin et al., (1987) suggested the existence of two hemocyte maturation lines in hematopoietic tissue of the ridgeback prawn, *Sicyonia ingentis* and reported four hemocyte categories based upon the presence, size and type of cytoplasmic granules and the presence of cytoplasmic deposits. The hemocyte categories were: agranular, small granule with cytoplasmic deposits, small granule without cytoplasmic deposits and large granule hemocytes. The division of cells were reported in a granular cells and small granule hemocytes without cytoplasmic deposits.

Hose et al (1992) reported hematopoiesis in paired epigastric hematopoietic nodules and studied the production and release of hemocytes throughout the molt cycle in the shrimp *Sicyonia ingentis*. They also reported the

morphological stages in the transition of hematopoietic stem cells into hyaline and granulocyte hemocytes.

Martin et al., (1993) described the same method of hemocyte maturation lines in the american lobster, *Homarus americanus* as in the case of penaeid shrimp *Sicyonia ingentis*.

Chaga et al.,(1995) described five types of hematopoietic cells in the hematopoietic tissue of the signal crayfish *Pacifastacus leniusculus* by means of differential interference contrast and Electron microscopy. Type 1 cells appeared to be non-differentiated and were located only in the apical parts of the lobules. Type 2 cells possess numerous cisternae of rough endoplasmic reticulum and granules with a striated structure. These cells occurred a more distal position in the lobules and were often found to divide. Type 3 cells were present in the distal parts of the lobules as well as in the interlobular spaces. They were characterised by large and swollen cisternae of the rough endoplasmic reticulum and numerous striated granules. Type 4 cells had two kinds of granules striated, which were similar to the granules of type 2,3 cells, and large refractile granules with a typical of granules inside the granular hemocytes.

Type 2,3 and 4 cells might represent the different stages of granular hemocyte development. Type 5 cells contain small, 0.3 – 0.6µm granules in their cytoplasm. They might be early precursors of semigranular hemocytes.

***MATERIALS
AND
METHODS***

MATERIALS AND METHODS

Experimental protocol:

Healthy Indian prawns (*Penaeus indicus* H.Milne Edwards) were collected by operating cast net from the co-operative prawn farms located at Vypeen island, Cochin (India). Prawns averaged 8.5 – 10gm were used in this study. Prawns were stocked in 50 liter plastic tub equipped with an air supply. Salinity and temperature were maintained at 17 ± 1 ppt and $28\pm 1^{\circ}\text{C}$ respectively.

Histological Techniques:

Healthy prawns were injected with Davidson's fixative of about 1% of their body weight (Bell and Lightner, 1988) using a 2cc tuberculin syringe fitted with a 21G-needle.

Injected prawns were cut into different tissues like 1st Maxillipede, 2nd Maxillipede, 3rd Maxillipede, 1st, 2nd, 3rd, 4th 5th pereopods, dorsal surface of the cephalothorax, and base of antenna region.

Soon after separation all the tissues were fixed in Davidson's fixative for 24 hours duration.

To aid in the localization of the hematopoietic tissues located on the dorsal side of the hepatopancreas on either of the forgut in the region of cephalothorax, indian ink (camel) was injected into the heart of live prawns (Martin et al., 1987). Approximately 2 minutes later shrimps were dissected and tissues were kept in a Davidson's fixative.

After 24hrs period of fixation, tissues of cephalothorax were left in decalcifying solution (1% Nitric acid in 70% Alcohol) for one to three days depending on the size of the tissues. The tissues were washed thoroughly in three changes of 70% isopropyl alcohol for 1 hr duration in each change.

The tissues were then dehydrated in ascending grades of isopropyl alcohol. First the tissues directly transferred to 70% alcohol, left for overnight. From 70% the tissues were transferred to 80% and then to 90% where they kept for one to two hrs each. Two changes were given in 100% alcohol for one hour each.

The tissues were cleared by immersing in alcohol – chloroform (1:1v/v) mixture followed by two changes of pure chloroform. The duration of treatment of tissues in alcohol – chloroform mixture, first chloroform change and second chloroform change were given for 3 hrs, overnight, and 6hrs respectively.

The tissues were kept in chloroform-wax mixture for 2 hrs and then transferred to paraffin wax (Merk, 58-60^oC M.P.) for infiltration. Three changes were given in molten wax for a duration of one hour each. Paraffin molded blocks were prepared and sections were cut at 5-6um thickness in rotary microtome.

The deparaffinised sections were stained with three different stains. The stains used were

- a) Mason's Trichrome stain (Melby and Altman, 1984)
- b) Van Gieson's stain (Melby and Altman, 1984) and
- c) Haemotoxylin – Eosin (Culling et al., 1985)

The stained sections were observed and photographed.

RESULTS

RESULTS

In the Indian white prawn *Penaeus indicus* (H.Milne Edwards), hematopoietic tissues were located on the dorsal surface of the hepatopancreas and dorso-lateral surface of the stomach, at the base of first two pairs of maxillipedes, around lateral arterial vessel, and antennal gland region. The location of hematopoietic tissues were shown in fig.1.

1. **Epigastric Hematopoietic Tissue:** Hematopoietic tissue was located on the dorsal surface of the hepatopancreas and stomach, which was arranged into nodules. Nodules were surrounded by thick connective tissue, lined with basement membrane. Each nodule was divided into lobules. Each lobule consisted of connective tissue capsule. Inner to the capsule, elongated spindle or pyramidal shaped, flattened cells with condensed nuclei were seen. Interdigitating with the flattened cells, there were large cells with abundant cytoplasm. Nuclei of these cells were either vesicular or homogeneous with prominent nucleoli. These cells had different staining characters, some appeared lightly basophilic without visible granules. Others cytoplasm appeared granular with basophilic or eosinophilic stain. Inside the lobule, cells of different morphology with homogeneous nuclei were observed. Abundant mitotic figures were noticed.

The large cells appeared to be stem cells undergoing various stages of differentiation. Inner to the stem cells, the cells appeared to be maturing into various types of hemocytes (fig: 2,3, 4,5,6).

2. Maxillipede Hematopoietic Tissue

2.1 **First maxillipede** : Hematopoietic tissue was arranged into lobules. The individual lobules were separated by a loose connective tissue fibres. The lobules were interspersed with hemal sinuses and totally surrounded by muscle tissue. In each lobule, stem cells with vesicular or homogeneous nuclei with prominent nucleoli were observed. The cytoplasm was dense, basophilic and appeared granular. Appearances of these cells were similar to that of stem cells described for epigastric nodule.

Cells of intermediate size having homogeneous nuclei and smaller cells with condensed nuclei were also seen. Large numbers of cells with different morphology were observed.

Many of the lobules contained only matured hemocytes and the stem cells were very limited in number, where as in other lobules, abundant number of stem cells were noticed. In these lobules, large number of stem cells were undergoing mitosis(fig: 7,8)

In certain lobules, one side was found to contain very thin connective tissue through which hemocytes escaping into the hemal sinuses(fig.9)

2.2 **Second maxillipede**: The appearance and structure of hematopoietic tissues were similar to the hematopoietic tissue of 1st maxillipede. They maintained same lobular structure and same type of cells constituted the hematopoietic tissue. However the lobules appeared small in size

and less in numbers. The hematopoietic activity was also reduced as indicated by less number of mitotic figures in each lobule (fig:10,11).

- 3 **Lateral arterial vessel:** Around the arterial vessel formation of hematopoietic tissue was noticed. The hematopoietic tissue was arranged into lobules. Wall of the lobules was surrounded by loose connective tissue and fibroblast like cells. Internal to the fibroblast cells, large cells were seen which were undergoing mitotic divisions. These large cells appeared to be stem cells or hemoblast cells. Internal to the stem cells, there were several types of hemocytes (fig:12,13).
- 4 **Antennal gland region:** In close association with antennal gland tubules or within the intertubular spaces several lobules were present. The lobules contained vesicular nucleated stem cells and dividing cells. Lobules were closely associated with hemal sinuses (fig:14,15,16).

FIGURES

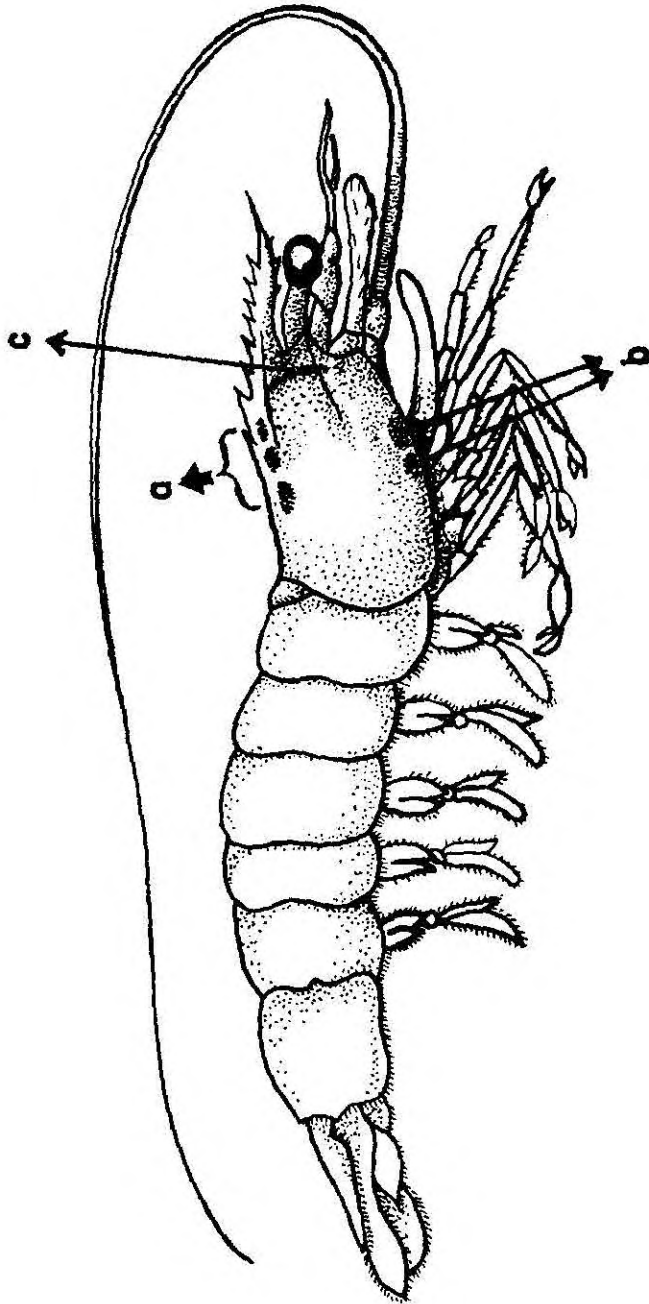


Fig. 1: Diagram of location of hematopoietic tissues in the Indian white prawn

Penaeus indicus.

- a. Epigastric hematopoietic tissue
- b. Maxillipede hematopoietic tissue
- c. Lateral arterial vessel hematopoietic tissue

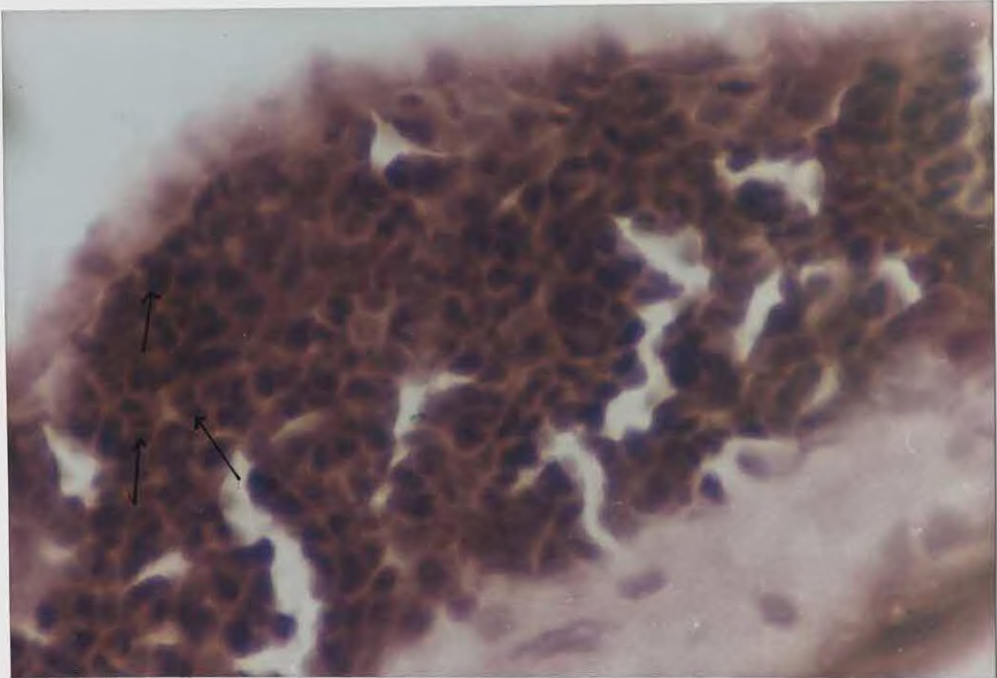
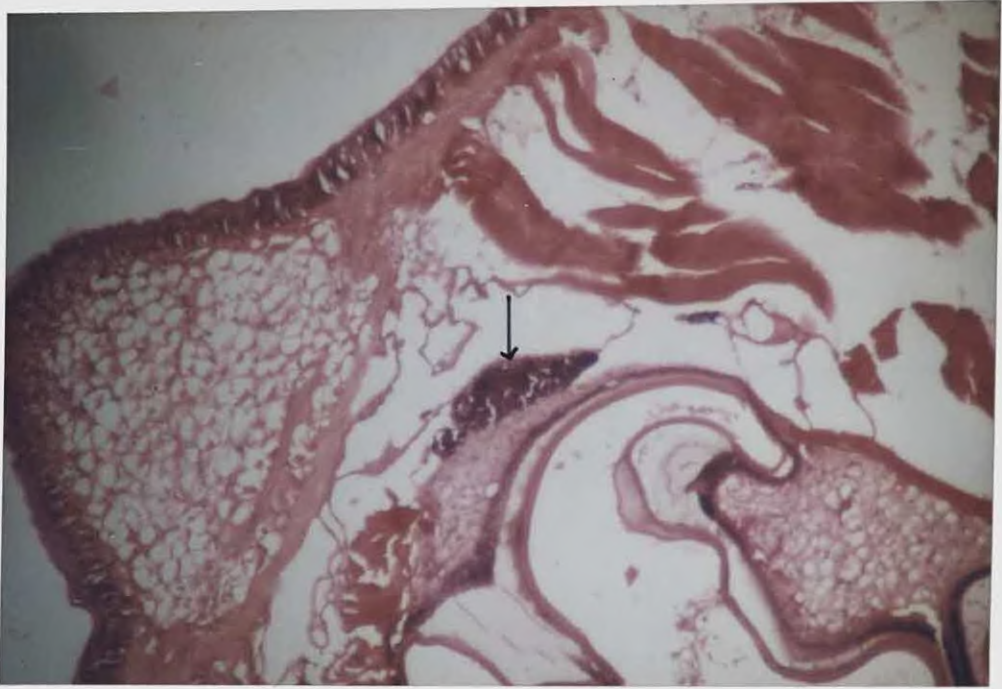


Fig. 2: Section of the stomach region showing hematopoietic tissue (arrow) on the epigastric region; H&E; 100X.

Fig. 3: Enlarged view of the Epigastric hematopoietic tissue showing the stem cells, maturing cells and mitotic figures (arrows); H&E; 400X.

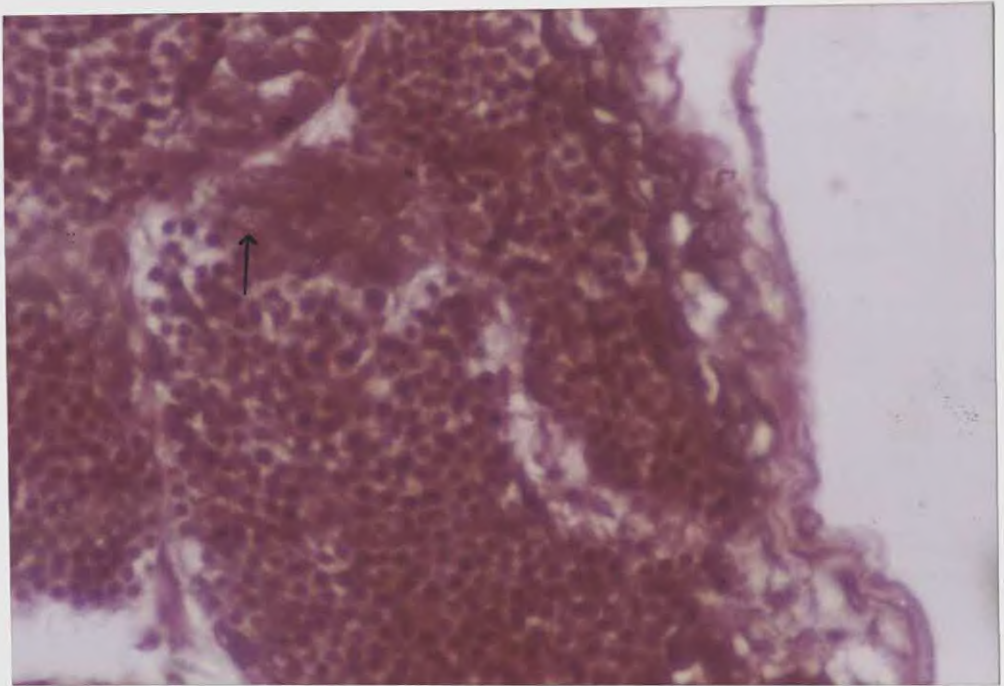
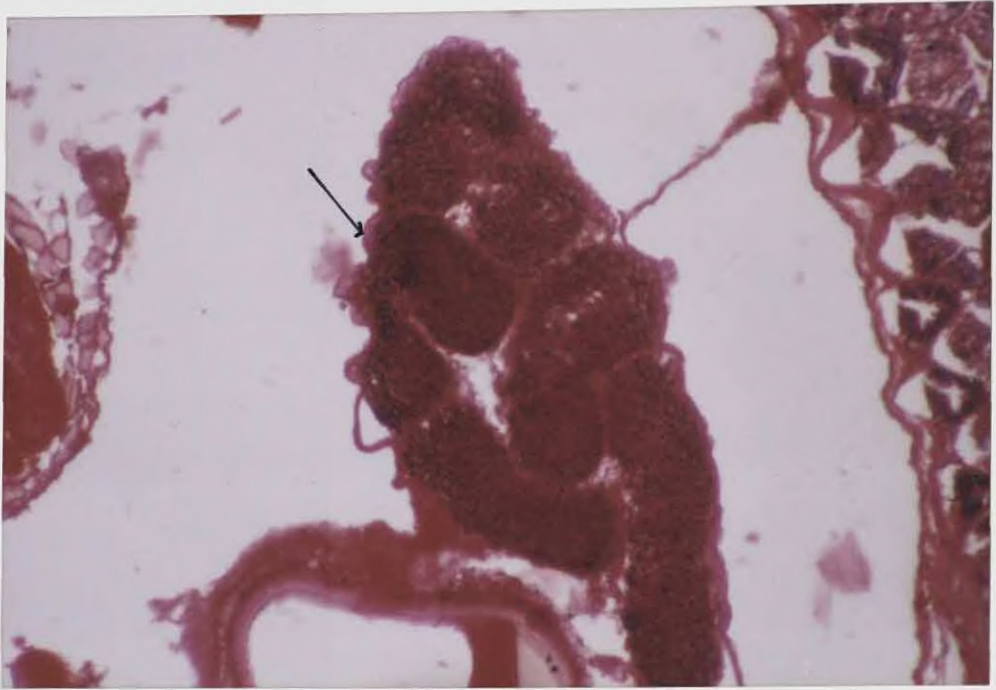


Fig. 4: Nodular structure of the Epigastric hematopoietic tissue (arrow). Within the nodule, lobules can be seen; Mason's Trichrome stain; 100X.

Fig. 5: Enlarged view of the epigastric hematopoietic tissue showing stem cells and maturing cells. The large cells with abundant cytoplasm are stem cells (arrow). Smaller cells are differentiating hemocytes at various stages; Mason's Trichrome stain; 400X.

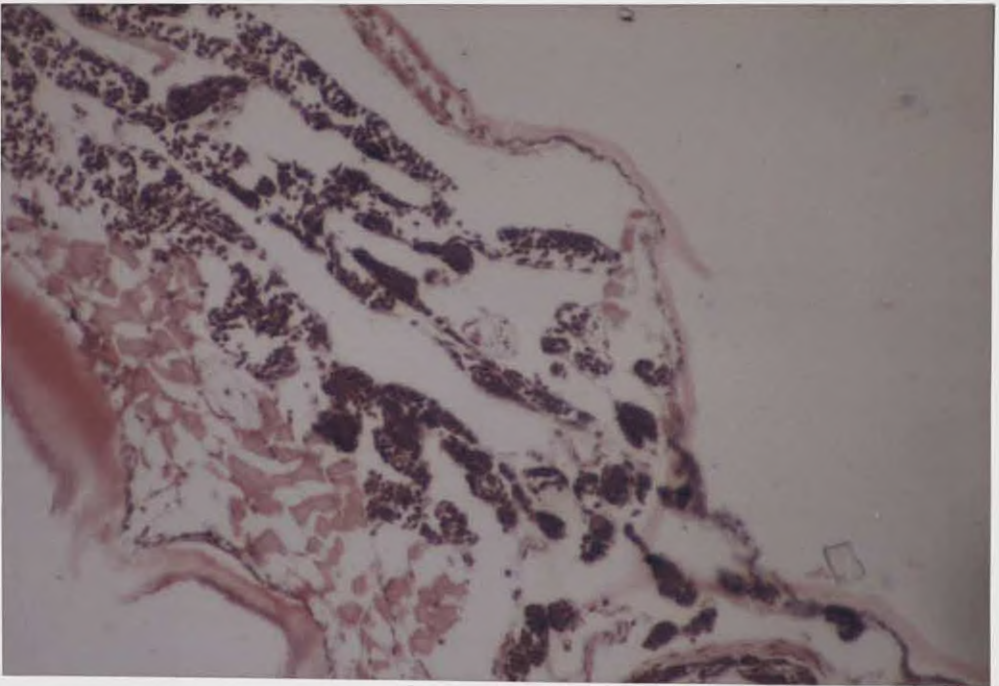
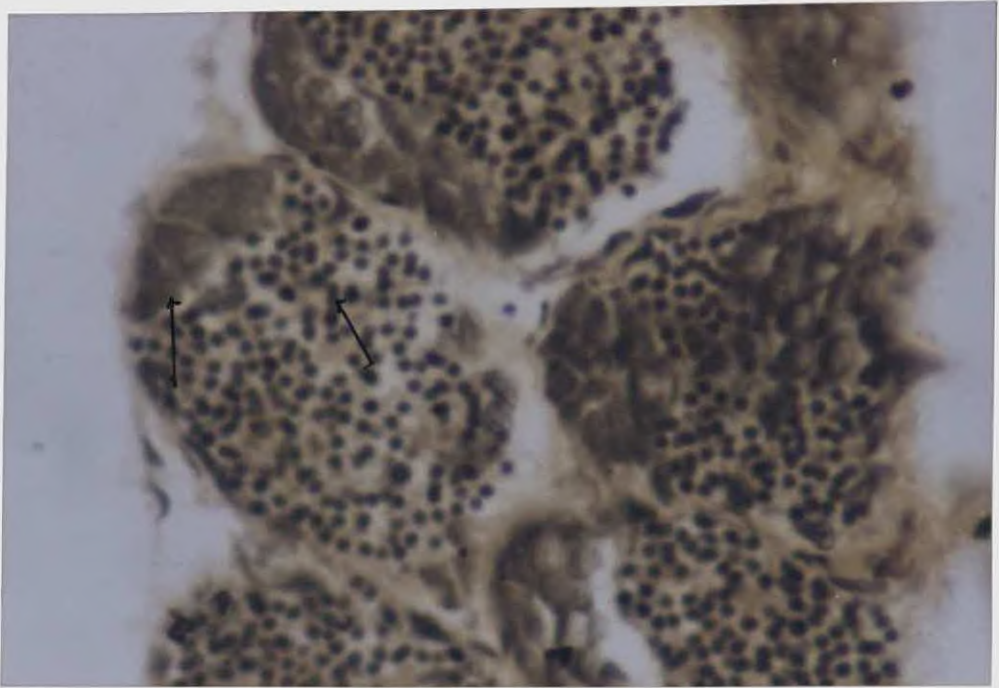


Fig. 6: Enlarged view of the epigastric hematopoietic tissue showing the lobules containing large stem cells and smaller cells. Smaller cells are differentiating into hemocytes (arrows); Van Gieson's stain; 400X.

Fig.7: Section of the first maxillipede showing extensive formation of hematopoietic tissue; Mason's Trichrome stain; 100X.

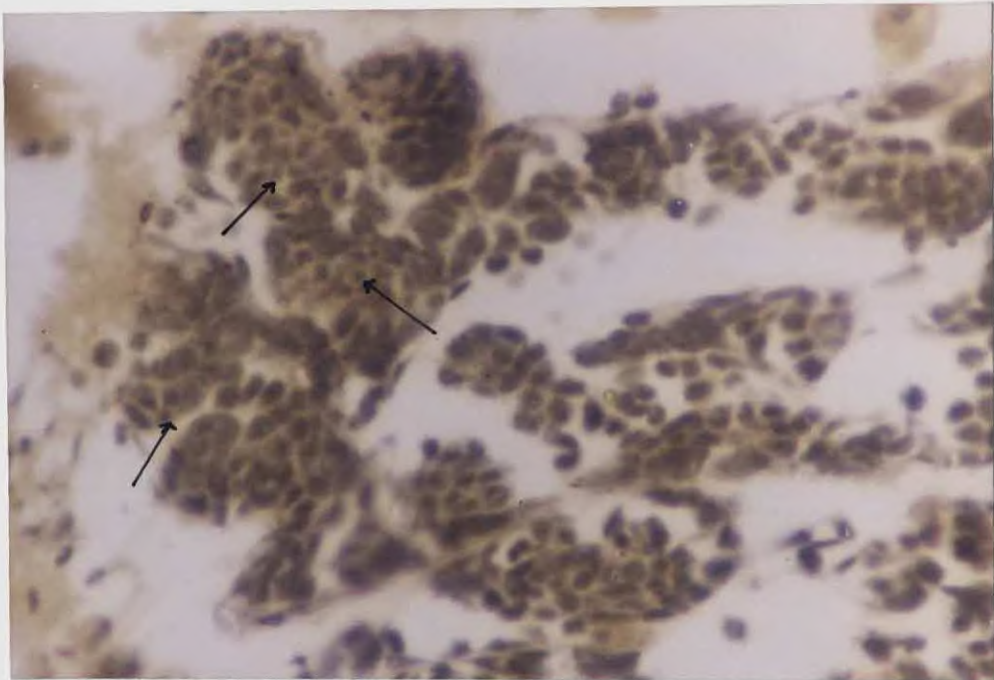
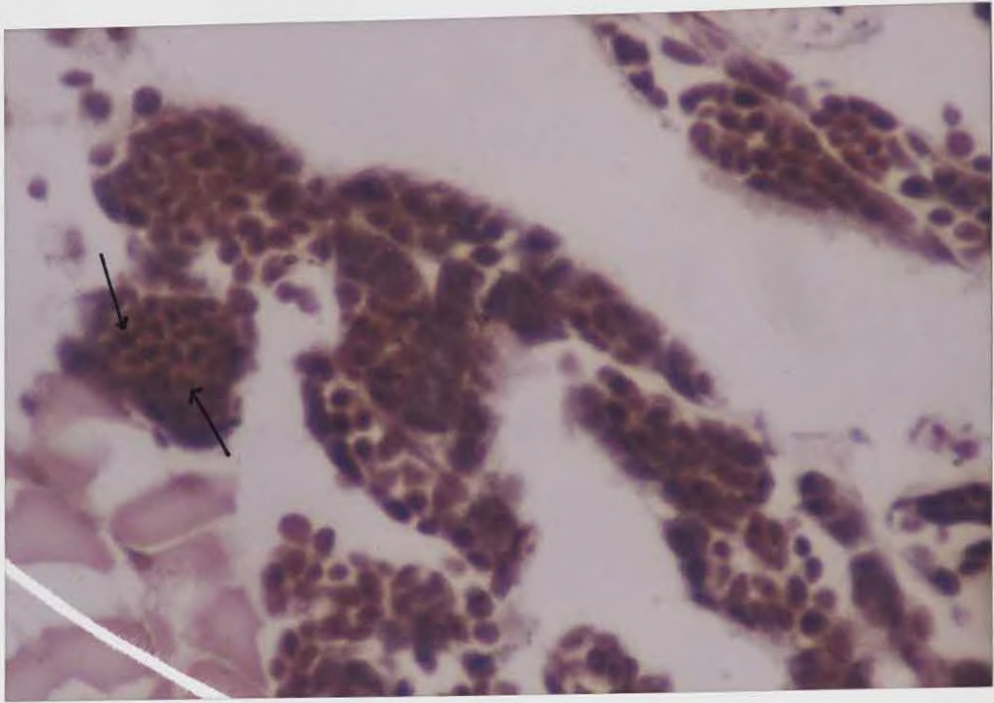


Fig. 8: Enlarged view of hematopoietic lobules in the first maxillipede. Several stem cells and differentiating hemocytes are seen in the lobules(arrows); Mason's Trichrome stain; 400X.

Fig. 9: Hematopoietic tissue of first maxillipede. In hematopoietic lobules active differentiation of hemocytes from stem cells can be seen . Hemocytes escaping into the hemal sinuses are also seen(arrows); Van Gieson's stain; 400X.

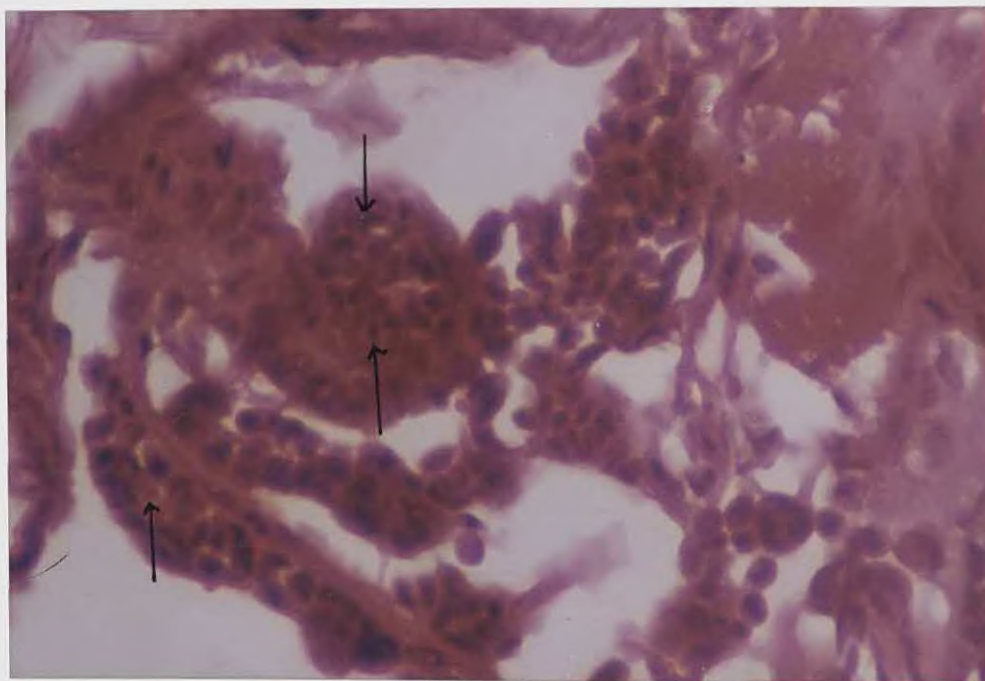
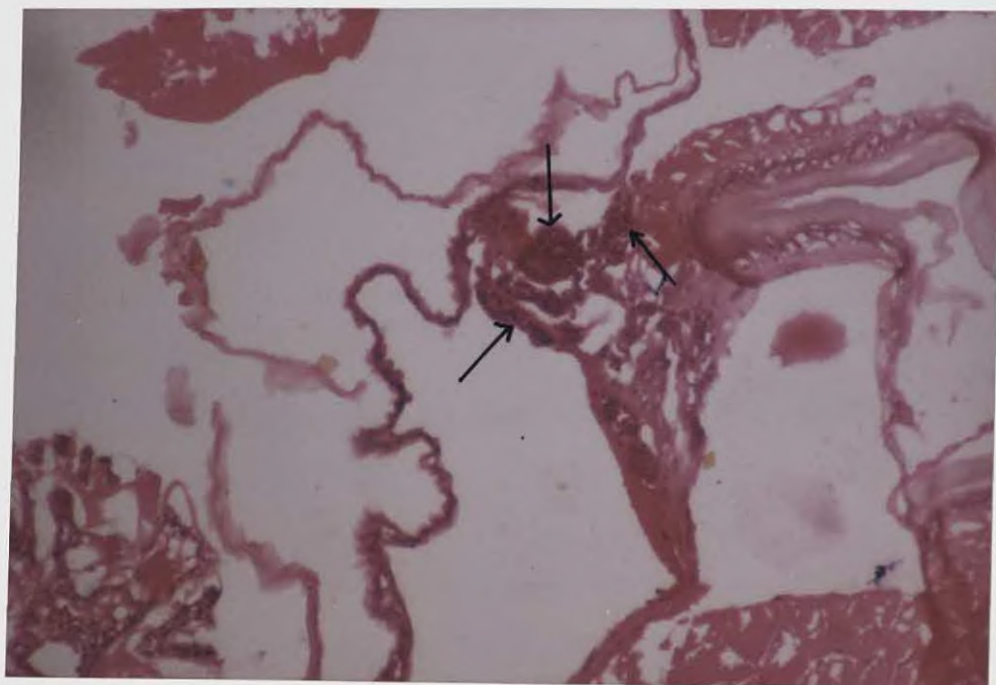


Fig. 10: Section of the second maxillipede showing focal areas of hematopoietic tissue (arrows); H&E; 100X.

Fig.11: Enlarged view of second maxillipede hematopoietic tissue showing stem cells, differentiating hemocytes, and mitotic figures can be seen(arrows); H&E; 400X.

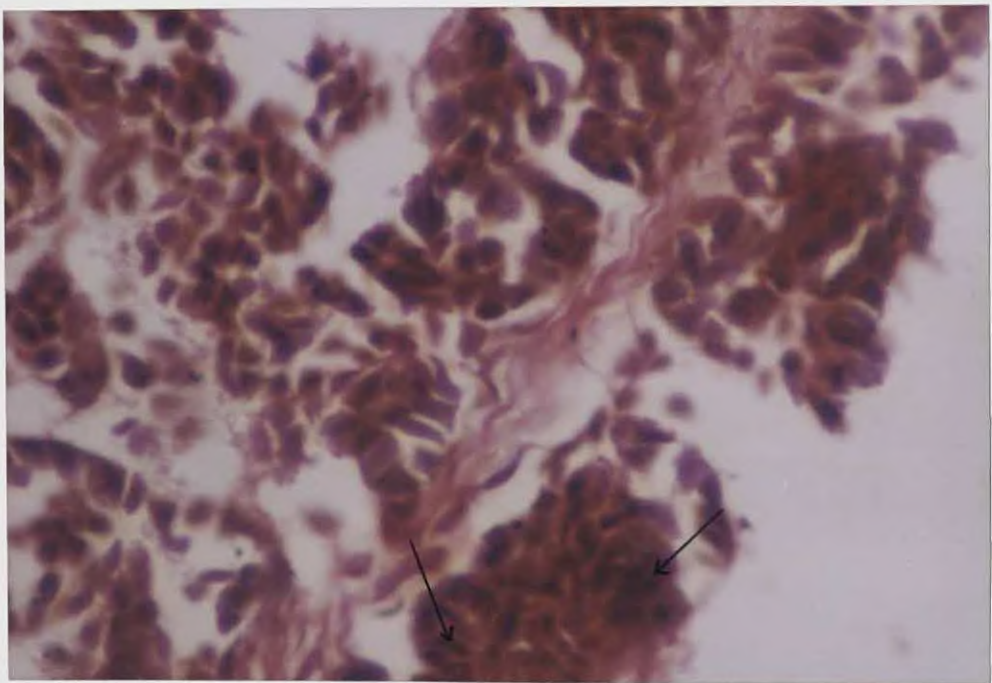
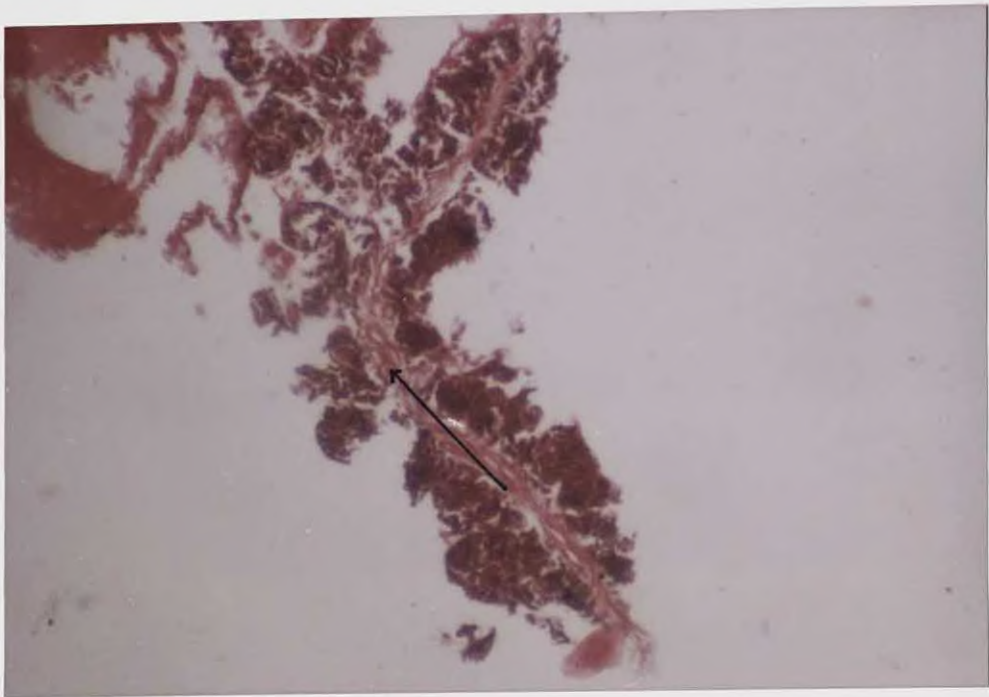


Fig. 12: Longitudinal section of lateral arterial vessel hematopoietic tissue. Lateral artery is shown by arrow. Several lobules are seen on the surface of lateral artery; Mason's Trichrome stain; 100X.

Fig. 13: Enlarged view of lateral artery hematopoietic tissue. Stem cells and differentiating hemocytes can be seen within the lobules(arrows); Mason's Trichrome stain; 400X.

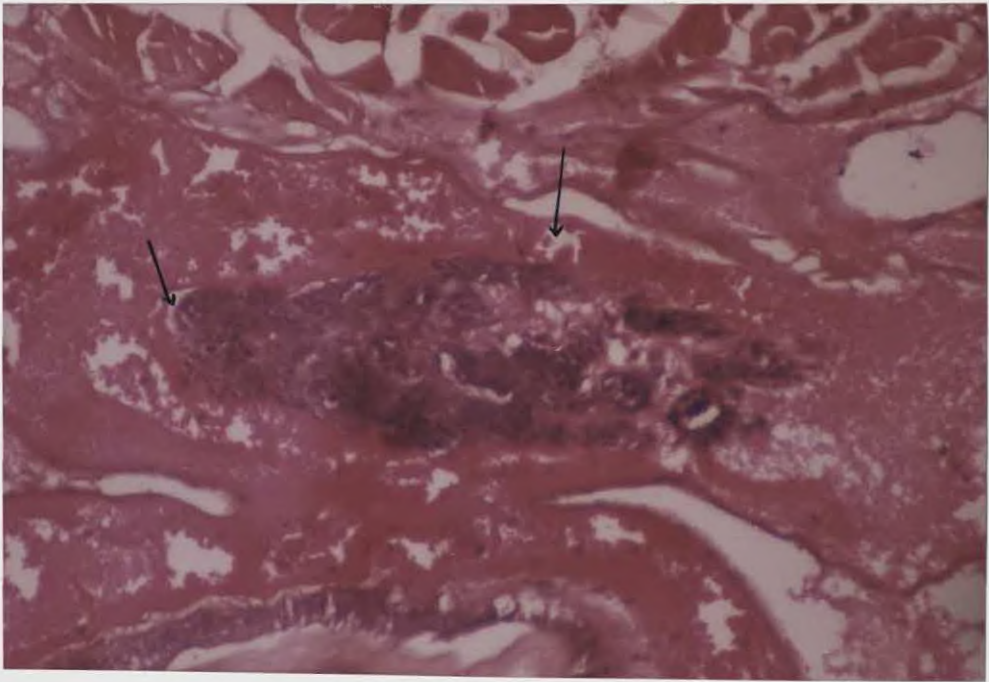
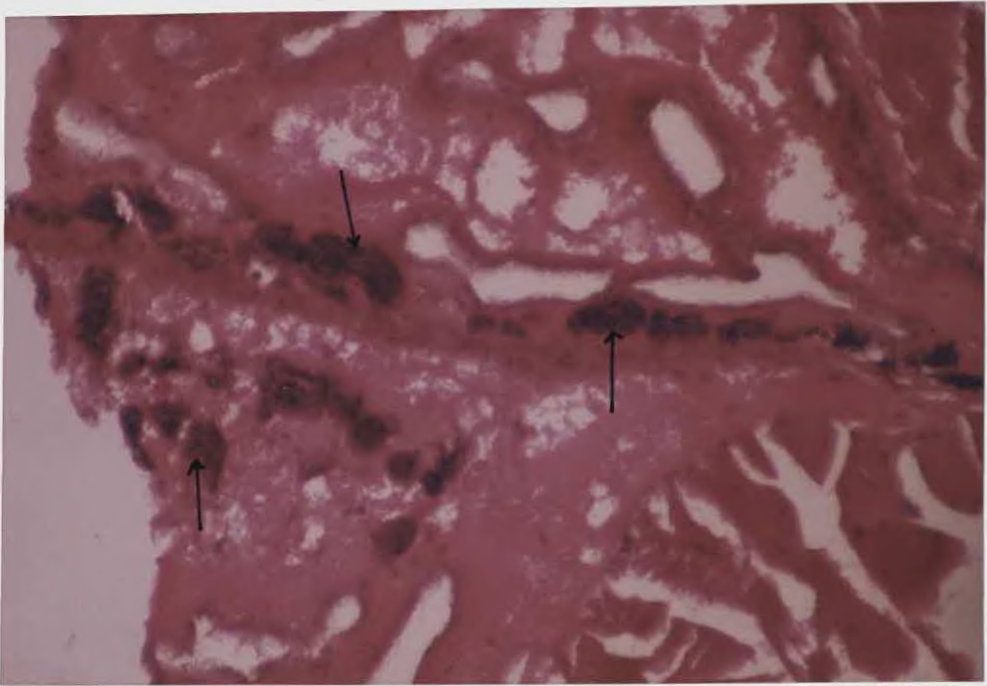


Fig.14: Section showing antennal gland region. Several lobules of hematopoietic tissue are dispersed in the antennal gland tubules (arrows);

H&E; 100X.

Fig.15: Section of a hematopoietic lobule in the antennal gland region, which is interspersed with hemal sinuses(arrow); H&E; 100X.

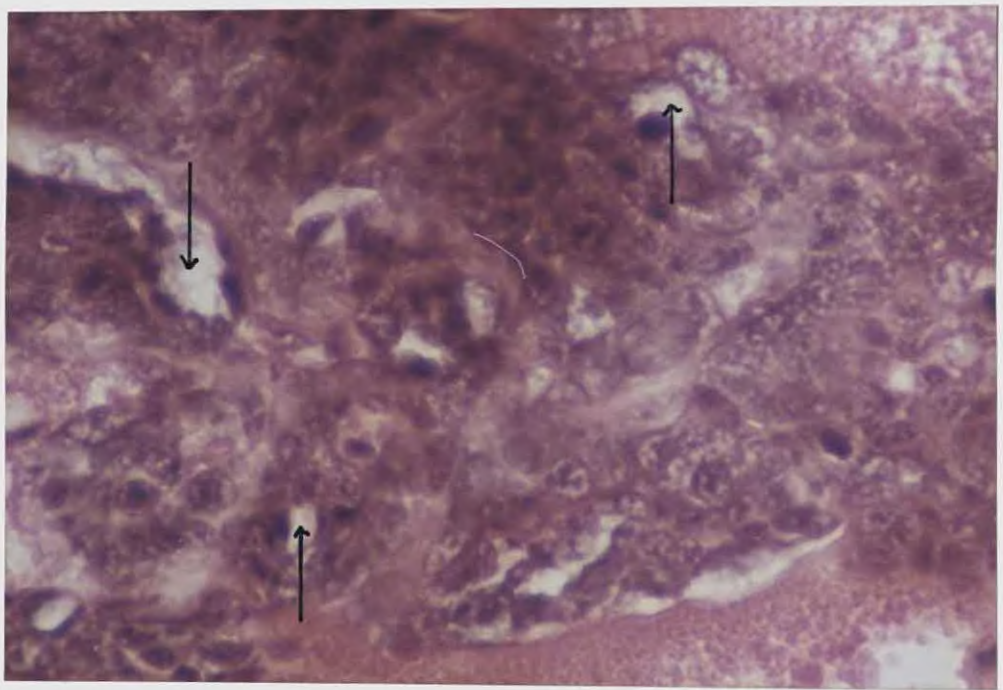




Fig. 16: Enlarged view of the hematopoietic lobule in the antennal gland region showing hemal lacunae(arrows); H&E; 400X.

DISCUSSION

DISCUSSION

The present study dealt with hematopoietic tissues of the Indian white prawn *Penaeus indicus*

In the Indian white prawn *Penaeus indicus* hematopoietic tissues were recorded on the dorsal surface of the hepatopancreas and stomach, at the base of first two pairs of maxillipedes, around lateral arterial vessel and antennal gland region.

Sheet like epigastric hematopoietic tissue have been found in crabs like *Carcinus maenas* (Ghiretti-Magaldi et al., 1977; Bazin, 1979), *Callinectes sapidus* (Johnson, 1980), *Pachygrapsus marmoratus* (Charmantier, 1972); in Cray fish like *Orconectes limosus* (Bohm and Gersch, 1983) *Pasifastacus leniusculus* (Chaga et al., 1995) and in lobsters like *Homarus americanus* (Martin et al., 1993).

Nodular epigastric hematopoietic tissue have been found in Penaeid shrimps like *Penaeus orientalis* (Oka, 1969), *Sicyonia ingentis* (Martin et al., 1987) and *Penaeus stylirostris* (Bell and Lightner, 1988).

In addition to the epigastric hematopoietic nodules, Bell and Lightner (1988) also reported the presence of hematopoietic tissues at the base of first three pairs of maxillipedes, around lateral arterial vessel and antennal gland region.

In the present study we could identify the hematopoietic tissue in all areas described by the above authors except in the third pair of maxillipedes. Since the above authors observations were in different crustacean species. The

different result obtained by us in *Penaeus indicus* may be due to species – specific or generic – specific difference. Hence it is an important observation.

In the Indian white prawn *Penaeus indicus* epigastric hematopoietic tissue was arranged into nodules, which were surrounded by a thick connective tissue layer lined with basement membrane. Nodules were composed of lobules, which were surrounded by connective tissue capsule. Inner to the capsule, large spindle or pyramidal shaped stem cells with flattened nuclei were recorded. Interdigitating with the spindle shaped cells, large cells with vesicular or homogeneous nuclei with prominent nucleoli were observed. Among these cells, some appeared basophilic without visible granules, others cytoplasm appeared granular with basophilic or eosinophilic stain.

Johnson (1980) described the lobular structure of epigastric hematopoietic tissue in the blue crab *Callinectes sapidus* which did not formed nodules. The lobular structure was observed in the present study also. But all lobules together were surrounded by a fibrous connective tissue forming a nodule.

Martin et al.,(1987) had reported nodular structure for the epigastric hematopoietic tissue of ridge back prawn *Sicyonia ingentis* and each nodule contained branched network of circular tubules surrounding the central hemal space and adjacent tubules were separated by loose connective tissue. Bell and Lightner(1988) also noted a nodular structure with lobules having fibrous connective tissue layer. The present observations were in conformity with that of Bell and Lightner (*loc.cit*). since Martin et al., (1987) had done their work using electron microscope they might have got better resolution. Hence the

tubular structure for the epigastric nodules could not be ruled out in the present case.

In the american lobster *Homarus americanus* Martin et al., (1993) studied the epigastric hematopoietic tissue and the tissue was composed of loosely attached ovoid lobules containing hematopoietic precursors and maturing hemocytes. The structure of the hematopoietic tissue was very similar to hematopoietic tissue described by Johnson (1980).

Chaga et al., (1995) reported the epigastric hematopoietic tissue of the freshwater cray fish *Pacifastacus leniusculus* which also were composed of lobular structure very similar to epigastric tissues of lobsters (Martin et al., 1993) and crabs (Johnson, 1980).

The present study broughtout that the epigastric tissue of shrimps were having a nodular structure as reported by Martin et al.,(1987) and Bell and Lightner (1988).

The cells composing the lobules were stem cells and various cells of differentiating stages containing agranular and granular cytoplasm. The cytoplasm stained differentially also. These types of cells were also reported in epigastric hematopoietic tissues of lobsters, cray fish, crabs, and shrimps (Johnson,1980; Martin et al., 1987; Hose et al., 1992; Martin et al., 1993; Chaga et al., 1995).

In the present study, hematopoietic tissues were noticed at the base of first and second pair of maxillipedes of the Indian white prawn *Penaeus indicus*. The hematopoietic tissue was arranged into lobules, which were seperated by

a loose connective tissue fibres. The lobules were interspersed with hemal sinues and totally surrounded by muscle tissue. In each lobule, stem cells with vesicular or homogeneous nuclei with prominent nucleoli were observed. The cytoplasm was dense, basophilic and appeared granular.

Bell and Lightner (1988) were the first authors to report the hematopoietic tissue in the maxillipedes of blue shrimp *Penaeus stylirostris*. They have reported the presence of hematopoietic tissue in three pairs of maxillipedes.

According to Bell and Lightner (1988), the hematopoietic tissue was organized into lobules, which were surrounded by thin fibrous connective tissue.

The loose connective tissue fibres surrounding the lobules of Indian white prawn were appeared similar to that of connective tissue fibres of blue shrimp. Structure of hematopoietic tissue in maxillipedes of *Penaeus indicus* in present study agrees with the observation of above authors (Bell and Lightner loc.cit). However in the present study hematopoietic tissues were noticed only in first two pairs of maxillipedes. In this respect our study differs with the observation cited above.

The internal structure of maxillipede hematopoietic tissue described in the present work was inconformity with follicular structure for epigastric hematopoietic tissue and sheet of epigastric hematopoietic lobules described in crabs *Carcinus maenas*, and *Callinectes sapidus* (Ghiretti – Magaldi et al., 1977; Johnson, 1980).

In the present work it was noticed that the hematopoietic tissue had composed of lobules very similar to epigastric hematopoietic tissue of crabs.

Bell and Lightner (1988) reported the formation of hematopoietic tissue around the lateral arterial vessel in the blue shrimp *Penaeus stylirostris*.

In the present study, we could identify the hematopoietic tissue around lateral arterial vessel. The tissue was arranged into lobules, which were surrounded by loose connective tissue. This structure of arterial vessel hematopoietic tissue was appeared similar to that of arterial vessel hematopoietic tissue of blue shrimp *Penaeus stylirostris*.

Hematopoietic lobules were also noticed in the antennal gland tubules or within the intertubular spaces of Indian white prawn *Penaeus indicus*. Bell and Lightner (1988) also reported the hematopoietic tissue in the antennal gland region of blue shrimp *Panaeus stylirostris*.

The present study revealed that hematopoietic tissue of *Penaeus indicus* was composed of epigastric nodules, tissue at the base of first two pairs of maxillipedes, lobules around lateral arterial vessel, and lobules in the antennal gland region. The epigastric nodules/tissues were reported earlier by many workers. However the presence of hematopoietic tissue in the region of maxillipedes, lateral arterial vessel and antennal gland region were reported only by Bell and Lightner (1988). We also reported the hematopoietic tissue at same locations with minor differences. This is an important finding. Detailed studies were required to elucidate the fine structure and maturation process of hemocytes in these locations.

SUMMARY

SUMMARY

1. White prawns (*Penaeus indicus*) were collected from co-operative prawn farm, Vypeen Island. These prawns were used for study of hematopoietic tissues using standard histological methods.
2. Hematopoietic tissues were recorded on epigastric region, at the base of first two pairs of maxillipedes, around lateral arterial vessel, and antennal gland region.
3. Epigastric hematopoietic tissue was formed of nodules, which were surrounded by thin connective tissue, lined with basement membrane. Each nodule was divided into lobules. Lobules were surrounded by connective tissue capsule and had spindle or pyramidal shaped, flattened cells with condensed nuclei and large cells. These large cells had abundant cytoplasm with vesicular or homogeneous nuclei. The large cells appeared to be stem cells undergoing various stages of maturation.
4. Maxillipede hematopoietic tissue was found at the base of first two pairs of maxillipedes.
5. First maxillipede hematopoietic tissue was arranged into lobules, which were separated by loose connective tissue fibres. In each lobule, stem cells had vesicular or homogeneous nuclei. The cytoplasm appeared dense, granular and basophilic. Appearances of these cells were similar to

that of stem cells described for epigastric hematopoietic nodule. Cells of intermediate size having homogeneous nuclei and smaller cells with condensed nuclei were seen.

6. The structure of second maxillipede hematopoietic tissue was similar to the hematopoietic tissue of first maxillipede. In the case of second maxillipede, hematopoietic lobules were small in size and less in number.
7. Hematopoietic tissue was found around the lateral arterial vessel. The tissue was organised into lobular units as described for maxillipede hematopoietic tissue.
8. Isolated hematopoietic tissues were also recorded among the antennal gland tubules or within the intertubular spaces. They maintained the same lobular structure.

REFERENCES

REFERENCES

❖ Allen, E.J. (1893)

Nephiridia and body-cavity of some decapod crustacea.

Q.J. Microsc. 34: 403-426

Bauchu, A.G., and Plaquet, J.C. (1973)

Variation du nombre des hématocytes chez les crustacés branchyours

Crustaceana 24: 215-223

Bauchu, A.G. (1981)

Crustaceans. In N.A. Ratcliffe and A.F. Rowley (eds): *Invertebrate Blood cells*,

Vol 2., New York: Academic Press, Pp. 386-420

Bazin, F. (1979)

Ultrastructure de l'organe hématopoïétique chez le crabe *Carcinus maenas*

Arch. Anat. Microsc. Morphol. Exp., 68: 142-157.

Bell, T.A., and Lightner, D.V. (1988)

A Hand book of Normal Penaeid Shrimp Histology. World Aquaculture Society. Lawrence. Kansas: Allen Press. 144Pp.

B'ohm, G.-A and M. Gersch (1983)

The hemopoietic character of the "Cephalic gland" in the cray fish

Orconectes limosus.

Gen.Comp.Endocrinol. 52: 102-107.

❖ Bruntz,L.(1907)

Etudes sur les organes lymphoïdes, phagocytaires et excréteurs des crustacés supérieurs

Arch.Zool.Exp. Gen. 7: 1-67.

Chaga, O.,Lignell,M. ,and Soderhall, K. (1995)

The haemopoietic cells of the freshwater cray fish. ***Pacifastacus leniusculus.***

Animal Biology 4(2) : 59-70.

Charmantier,M. (1972)

E'tude préliminaire de la leucopoïèse chez ***Pachygrapsus marmoratus*** (Crustacé, Décapode) au cours du cycle intermue.

C.R.Acad.Sci.Ser.D 275 : 683 – 686

Claes, M.F., and Morse, M.P. (1991)

Is the white body the blood forming tissue in cephalopods?.

American Zoologist. Vol.31, no.5, Pp.130A

❖ Cue'not,L. (1893)

E'tudes physiologiques sur les Crustacés Décapods.

Arch.Biol.Lieges 13:245-303.

❖ Cue'not,L. (1904)

L'organe phago cytaire des Crustace's De'capode's.

Arch.Zool.Exp.Gen. 111:1-15

Culling, C.F.A., Allison, R.T. , and Barr, W.T. (1985)

Cellular Pathology Technique. 4th edn, Butterworth, London, 391Pp.

❖ Demal,J. (1953)

Gen'ese et differenciation d'he'mocytes chez *Palaemon varians* Leach.

Cellule 56 : 87-102

Durliat,M. (1985)

Clotting process in crustacea Decapoda

Biol.Rev. 60:473-498

Durliat,M.(1992)

Coagulation in crustacea Decapoda

Source: First European crustacean conference, Paris, August 31-September

5, 1992. 49 Pp

❖ Fontaine,C.T. and Lightner,D.V. (1973)

Observations on the process of wound repair in penaeid shrimp.

J.Invt.Pathol. 22:23-33.

❖ George, W.C., and Nichols, J. (1948)

A study of the blood of some crustacea.

J. Morph., 83: 425-443

Ghiretti – Magaldi, A., Milanese, C., Tognon, G. (1977)

Hemopoiesis in crustacea Decapoda: Origin and evolution of hemocytes and cyanocytes of ***Carcinus maenus***.

Cell. Diff. 6: 167-186.

Hose, J.E., Lightner, D.V., Redmann, R.M., Danald, D.A. (1984)

Observations on the pathogenesis of the imperfect fungus, ***Fusarium solani***, in the California brown shrimp, ***Penaeus californiensis***.

J. Invt. Pathol. 44: 292-303.

Hose, J.E., Martin, G.G., Nguyen, V.A., Lucus, J., Rosenstein, T. (1987)

Cytochemical features of shrimp hemocytes.

Biol. Bull. 173: 178-187

Hose, T.E., Martin, G.G. (1989)

Defense functions of granulocytes in the ridge back prawn ***Sicyonia ingentis***

J. Invt. Pathol. 53: 335-346

Hose, J.E., Martin, G.G., Gerard, A.S. (1990)

A decaped hemocyte classification scheme integrating morphology, cytochemistry and function.

Biol. Bull. 178:33-45

Hose, J.E., Martin, G.G., Tiu, S. , Mckrell, N. (1992)

Patterns of hemocyte production and release throughout the molt cycle in the penaeid shrimp, ***Sicyonia ingentis***.

Biol. Bull. 183:185-199.

Johnson, P.T.(1980)

Histology of the blue crab, ***Callinectes sapidus***: A model for the Decapoda. Newyork: Praeger, 440 Pp.

Karin van de Braak and wpw van der knaap (1998)

Morphological, antegenic and functional characteristics of ***Penaeus monodon*** hemocytes. Source: Workshop on shrimp immunity and disease control. An integrated approach, Chiang mai, Thailand November 8-10, 1998.

❖ Kollman, M.(1908)

Recheerches sur les leucocytes et le tissue lymphoide des inverte'bre's.

Ann. Sci. Nat. Zool. Ser. 9, 8:1-240

Krol, R.A., Hawkins, W.E., Volgelbein, W.K., Overstreet, R.M. (1989)

Histopathology and ultrastructure of the hemocyte response to bacterial infection in cultured ***Penaeus vannamei***.

J. Aquat. Anim. Health 1:37-42

Lightner, D.V., Redman, R.M., Price, R.L., Wiseman, M.O. (1982)

Histopathology of aflatoxicosis in the marine shrimp *Penaeus stylirostris* and *P. Vannamei*.

J. Inver. Pathol. 40:279-291.

Lightner, D.V., Redman, R.M., Bell, T.A. (1983)

Intectious hypodermal and hematopoietic necrosis, a newly recognized virus disease of penaeid shrimp.

J. Inver. Pathol. 42:62-70.

❖ Marrec, M. (1944)

L'organe lymphocyto-gène des crustacés décapodes. Son activité cyclique

Bull. Inst. Oceanogr. Mon. (Monaco) 867. 4Pp.

Martin, G.G., Graves, B.L. (1985)

Fine structure and classification of shrimp hemocytes.

J. Morphol. 185:339-348.

Martin, G.G., Hose, J.E., Kim, J.J. (1987)

Structure of hematopoietic nodules in the ridge back prawn, *Sicyonia ingentis*: light and electron microscopic observations.

J. Morphol. 192:193-204.

Martin, G.G., Hose, J.E., Corzine, J. (1989)

Morphological comparison of major arteries in the ridgeback prawn, ***Sicyonia ingentis***.

J.Morphol. 200:175-183.

Martin, G.G., and Hose, J.E. (1992)

Vascular elements and blood (hemolymph), In Microscopic anatomy of invertebrates. Vol X, Decapod crustacea. Pp:117-146

Martin, G.G., Hose, J.E., Maryanne Choi, Ron Provost, Gregg Omori, Nancy Mckrell, and Garret Lam (1993)

Organization of Hematopoietic tissue in the intermolt lobster, ***Homarus americanus***.

J.Morphol. 216:65-78

Maynard, D.M. (1960)

Circulation and heart function. In T.H. Waterman (ed.): The physiology of crustacea. New York: Academic press, Pp. 161-226

Melby, E.C. Jr. and Altman, N.H. (Eds.) (1984)

CRC Hand book of Laboratory Animal Science.

Vol.2, CRC Press, Florida, 265 Pp.

Oka, M (1969)

Studies on *Penaeus orientalis* kishinouge. VIII. Structure of newly found lymphoid organ.

Bull. Jpn. Soc. Sci. Fish. 35:245-250.

Omori, S., Martin, G.G., Hose, J.E. (1989)

Morphology of hemocyte lysis and clotting in the ridge back prawn,

Sicyonia ingentis.

Cell Tiss. Res. 255:117-123.

Smith, V.J. and Ratcliffe, N.A. (1980)

Host defense reactions of the shore crab. *Carcinus maenas*: clearance and distribution of injected test particles.

J. Mar. Biol. Ass. U.K., 60:89-102

Soderhall, K., and Cerenius, L. (1992)

Crustacean immunity.

Ann. Rev. Fish. Diseases. Pergamon Press, Pp.3-23.

❖ Stang-Voss, C. (1971)

Zur ultrastruktur der blutzeller wibelloser tiere. V. Ueber die Hamocyten Von

Astacus astacus (L.) crustacea.

Z. Zellforsch., 122:68-75

Tsing, A., Arcier, J.M., Brehe'lin, M. (1989)

Hemocytes of penaeid and palaemonid shrimps: Morphology, cytochemistry and hemograms.

J. Invert. pathol. 53:64-77.

Vacca, L.L., and Fingerman, M. (1983)

The roles of hemocytes in tanning during the molt cycle: A histochemical study of the fiddlercrab, *Uca pugilator*.

Biol. Bull. 165:758-777

White, K.N., and Ratcliffe, N.A. (1982)

The segregation and elimination of radio and fluorescent labeled marine bacteria from the hemolymph of the shore crab, *Carcinus maenas*.

J. mar. Biol. Ass. U.K. 62:819-833.

White, K.N., Ratcliffe, N.A., Rossa, M. (1985)

Antibacterial activity of hemocyte clumps in the gills of shore crab,

Carcinus maenas.

J. Mar. Biol. Ass. U.K. Vol. 65, Pp. 857-870.

Williams, A.J. and Peter. L. Lutz (1975a)

The role of the hemolymph in the carbohydrate metabolism of *Carcinus maenas*.

J. Mar. Biol. Ass., U.K. 55:667-670.

Williams, A.J, and Peter.L.Lutz (1975b)

Blood cell types in ***Carcinus maenas*** and their physiological role.

J.Mar.Biol.Ass., U.K.55: 671-674.

❖ Not referred in original