



Note

***Amyloodinium ocellatum* infestation in the broodstock of silver pompano *Trachinotus blochii* (Lacepede, 1801) and its therapeutic control**

P. RAMESH KUMAR, A. K. ABDUL NAZAR, R. JAYAKUMAR, G. TAMILMANI,
M. SAKTHIVEL, C. KALIDAS, V. BALAMURUGAN, S. SIRAJUDEEN, R. THIAGU
AND G. GOPAKUMAR

Mandapam Regional Centre of Central Marine Fisheries Research Institute, Mandapam - 623 520

Tamil Nadu, India

e-mail: drggopakumar@gmail.com

ABSTRACT

A case of *amyloodiniosis* caused by infestation of the dinoflagellate *Amyloodinium ocellatum* in the silver pompano (*Trachinotus blochii*) maintained for broodstock development is reported. Grossly, erosion of the operculum and excessive secretion of mucus on gills was observed. Microscopic examination of gill filaments showed the presence of trophonts. Histopathologically, gills showed erosion and necrosis of the primary and secondary lamellae. The causative organism *A. ocellatum* was identified based on the clinical signs as well as gross and microscopic examinations. Among many treatment methods tested, dip treatment with chloroquine phosphate (500 mg per 100 l of water) or with low saline water mixed with *Oodinol 1000* were found useful in healthy maintenance of silver pompano broodstock.

Keywords: *Amyloodiniosis*, Broodstock, Dinoflagellate, Infestation, Silver pompano, *Trachinotus blochii*

The dinoflagellate *Amyloodinium ocellatum* spends a portion of its life cycle as a parasitic organism and the disease caused by this organism is commonly referred to as *amyloodiniosis* or marine velvet disease. The parasitic stage of *A. ocellatum*, known as trophont is the feeding stage. The trophont attaches to the fish by anchor-like roots or rhizoids and infests the gills, fins and body of the host fish (Schwarz and Smith, 1998). It feeds on the epithelial tissues of the skin and gills for several days before detaching from the host to become the tomont. The tomont is an encysted stage that subdivides internally to form more than 200 numbers of infective dinospores (Reed and Francis-Floyd, 1994). There are many reports of *A. ocellatum* infection and its pathogenicity in mariculture and aquarium systems (Noga and Levy, 2006). *A. ocellatum* has a broad host and geographic range causing fish mortalities in tropical and temperate environments. Paperna (1980) described heavy infestation of *A. ocellatum* in cultured gilthead bream and seabass. Rapid spread of the parasite leading to high mortality are common in cultured fish if the organism is not recognised and treated early in the course of outbreak (Montgomery-Brock *et al.*, 2000).

A. ocellatum infections have been reported in commercially important shrimp and prawn species

viz., *Fenneropenaeus indicus*, *Penaeus monodon*, *Penaeus semisulcatus*, *Macrobrachium rosenbergii* and *Macrobrachium malcomsonii* with moderate to intense tissue reactions (Aravindan *et al.*, 2007). Kizhakudan *et al.* (2014) have reported mortality of juvenile Indian halibut *Psettodes erumei* due to *A. ocellatum* infestation. Kuperman and Matey (1999) reported massive infestation of *A. ocellatum* in young tilapia in a highly saline lake Salton Sea, California, USA. Outbreak of the infestation and subsequent mortality of young fish was registered at water temperature and salinity of 40°C and 46 ppt respectively. Outbreak of *amyloodiniosis* was reported by Saraiva *et al.* (2011) in farmed turbot in Portugal and by Pereira *et al.* (2011) in farmed gilthead seabream. *A. ocellatum* can withstand a wide range of salinity (10 to 60 ppt) and temperature (16 to 30°C) (Paperna, 1984a). The cellular division within the tomont ceases at water temperatures below 10°C, but can be completed within 3 to 5 days at water temperatures of 22 to 25°C.

This paper describes a case of *amyloodiniosis* in the silver pompano (*Trachinotus blochii*) broodstock maintained at the Mandapam Regional Centre (MRC) of Central Marine Fisheries Research Institute (CMFRI), Tamil Nadu, India and the results of the treatment trials undertaken.

Silver pompano (mean length: 20 cm; mean weight: 1.50 kg) were maintained for broodstock development and captive breeding in 10 t capacity FRP tanks, holding seawater (salinity: 30-34 ppt, dissolved oxygen: $>5 \text{ mg l}^{-1}$, pH: 7.4 to 8.2, temperature: $29-32^{\circ}\text{C}$) with continuous aeration and flow-through seawater system. The stocking density was maintained at 1 kg biomass per t of water. On 25th August 2012, fish exhibited loss of appetite and sluggish swimming behaviour with mortality (20%). Dead and moribund fish were subjected to microscopic and histopathological examinations. Gill filaments and skin scrapings from moribund fish were collected for microscopic examination for pathogenic/parasitic infection (Noga *et al.*, 2006) if any. Gills collected from both freshly dead and moribund fish were preserved in 10% neutral buffered formalin (NBF) for histopathological analysis. The tissues were processed, embedded in paraffin wax, sections cut at 4μ thickness and stained with haematoxylin and eosin (Lillie and Fulmer, 1976). The internal organs of dead fish were also examined for presence of any lesions. The rearing tank water was also examined for the presence of tomonts.

A total of five dip treatment regimes for a period of seven days were designed to control *amyloodiniosis* in silver pompano broodstock: filtered seawater containing i) 25 ppm formalin; ii) 25 ppm H_2O_2 ; iii) chloroquine phosphate (10 ppm); iv) low saline water (5‰); and v) low saline water mixed with *Oodinol 1000* (JBL GmbH & Co., Germany; 10 ml per 100 l of water). The volume of water in the treatment tanks in all regimes was 250 l. The dosage levels of formalin, H_2O_2 and chloroquine phosphate were selected based on published literature available on treatment of various marine food fish and ornamental fish (Paperna, 1984b; Lewis *et al.*, 1988; Montgomery-Brock *et al.*, 2000). Low saline water was chosen for therapeutic purpose as reported by Francis-Floyd and Floyd (2011). Concentration of *Oodinol 1000* used was as recommended by the manufacturer. Moderately infected

fish (75 nos.) were divided into fifteen groups of five each. Each treatment was performed in triplicates. Duration of all the dip treatment was 15 min. Mucus was collected from gill and body surfaces of the fish before and after dip-treatments. Before shifting the treated fish to their respective tanks post-treatment, tanks were cleaned by scrubbing the sides as well as bottom and washed with freshwater. Effects of treatments on detachment of the trophonts and recovery of fish were studied. The detachment of trophonts and its numbers were assessed by examining the sediment of the treatment tank water and also by examining gill filament swab from the fish prior to and after treatment. The final survival percentage in each treated group was calculated on termination of treatment. The data on fish survival percentage were statistically analysed employing one way ANOVA (SPSS 20.0 statistical package, SPSS Inc., USA).

The infected fish showed signs of distress, loss of appetite and flashing behaviour. The body of silver pompano infested with *A. ocellatum* appeared thin and emaciated. Grossly, focal areas of erosion were seen on the operculum. Gills of infected fish showed excessive mucus and pale discoloration. It is presumed that fish died due to severe erosion of gill membranes hampering gaseous exchange. Microscopic examination of the gill filaments showed distended appearance with the presence of feeding stage trophonts, dark-brown in colour mechanically lodged between the gill filaments (Fig. 1). Dislodged trophonts were also observed between the gill lamellae and on the fin surface (Fig. 2). Histopathologically, the gill filaments showed hypertrophy of the secondary lamellae with the presence of inflammatory cells around the trophonts (Fig. 3). Secondary lamellae showed focal necrotic changes. In histological sections trophonts were also seen inside the gill arch and tissues (Fig. 4). Internal organs showed generalised congestion. The cysts collected from the rearing tank water were also confirmed as tomonts of *A. ocellatum*.

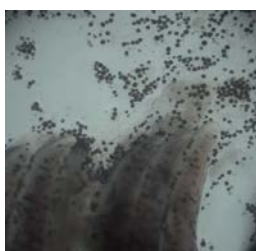

Fig. 1. Wet mount of silver pompano gills showing trophonts and detached tomonts of *A. ocellatum*



Fig. 2. Caudal fin of silver pompano showing erosion due to *A. ocellatum* infestation

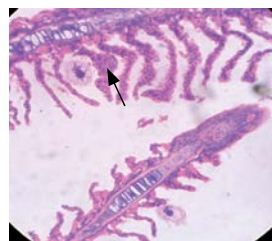


Fig. 3. Section of gills showing hypertrophy and necrosis (arrow) of the secondary lamella around the trophonts (H&E; x 100).

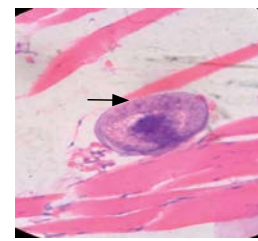


Fig. 4. Section of gill arch showing infestation with trophont of *A. ocellatum* (arrow) (H&E; x400)

The treatment methods tried and resultant survival percentage are presented in Table 1. Of the five types of dip treatment procedures followed in the present study, the treatment with chloroquine phosphate showed better results with a mean survival percentage of 100 followed by treatment with low saline water mixed with *Oodinol 1000* which resulted in a mean survival of 86.67%. In both these treatments, the fish resumed feeding immediately after the first day of treatment indicating that the fish quickly recovered from the stress caused by *A. ocellatum* infestation. The treatments with formalin, H₂O₂ and low saline water resulted in mean survival of 73.33, 53.33 and 33.33%, respectively. Fish in the above three treatment groups resumed feeding from third day of commencement of treatment. Survival percentage showed significant difference ($p < 0.01$) between different treatments.

Table 1. The methods of treatments employed and results of survival percentage

Chemical used	Dose	Duration of exposure	Mean survival (%)
Formalin	25 ppm	15 min	73.33
Hydrogen peroxide	25 ppm	15 min	53.33
Chloroquine phosphate	10 ppm	15 min	86.67
Low saline water	5 ppt	15 min	100
Oodinol 1000	25 ml	15 min	100

Chloroquine phosphate, an antimalarial compound, was reported to be effective in control of *A. ocellatum* at a concentration of 10 mg l⁻¹, but the system may need re-dosing after 7 or 8 days (Lewis *et al.*, 1988). The usage of chloroquine phosphate to control *A. ocellatum* in fishes reared for human consumption is not recommended (Francis-Floyd and Floyd, 2011). This compound has been proved safe and effective in controlling *A. ocellatum* in marine aquarium fish and it has been successfully used to save broodstock of food fishes for breeding purpose. However, residual level of chloroquinone phosphate has not been reported in the eggs or larvae of the treated broodstock fish. The commercial preparation, *Oodinol 1000* contains copper sulphate pentahydrate and methylthioninium chloride at 1260 mg and 4 mg per 100 ml, respectively. Copper is most commonly used for control of *amyloodiniosis* in the United States. It was reported that copper was gradually added to the culture water till the free copper ion (Cu²⁺) reached a concentration of 0.2 mg l⁻¹ and this level was maintained up to a period of 3 weeks (Francis-Floyd and Floyd, 2011). This treatment was not effective against the tomonts, but only helped in dislodging the parasitic trophonts. Repeated treatments were reported to be required for maintaining the health of the fish (Reed and Francis-Floyd, 1994).

Benzalkonium chloride was also reported to be useful for the control of *amyloodiniosis* with limited success (Schwarz and Smith, 1998). The best possible practice to prevent *amyloodiniosis* in intensive aquaculture system is mechanical filtration of seawater using micro screen drum or bead filters. This helps to physically remove the tomont stage from the production system (Schwarz and Smith, 1998). Best management practices involving periodical (once in 7 days) scrubbing and cleaning of tanks with freshwater, subjecting the brood fish to dip treatment with chloroquine phosphate (10 ppm) or with low saline water mixed with *Oodinol 1000* and cleaning of all filtration or recirculation systems are found to be helpful in healthy maintenance of silver pompano broodstock.

Acknowledgements

The authors are thankful to the Director, Central Marine Fisheries Research Institute, Kochi, India, for providing required facilities and encouragement for carrying out this study.

References

- Aravindan, N., Kalavati, C and Aravindan, S. 2007. Protozoan parasites in commercially important shrimp species from north-east coast of Andhra Pradesh, India. *J. Exp. Zool.*, 10 (1): 9-20.
- Francis-Floyd, R. and Floyd, M. R. 2011. *Amyloodinium ocellatum*, an important parasite of cultured marine fish. *SRAC Publication No. 4705*, Southern Regional Aquaculture Center, 11 pp.
- Kizhakudan, J. K., Praveena, P. E and Maran, B. A. V. 2014. Investigation on the mortality of juveniles in captive stock of the Indian halibut *Psettodes erumei*. *Indian. J. Geo Mar. Sci.* (In press).
- Kuperman, B. I. and Matey, V. E. 1999. Massive infestation by *Amyloodinium ocellatum* (Dinoflagellida) in a highly saline lake, Salton Sea, California, USA. *Dis. Aquat. Org.*, 39: 65-73.
- Lewis, D. H., Wenxing, A., Ayers, A. and Arnold, C. R. 1988. Preliminary studies on the use of chloroquine as a systemic chemotherapeutic agent for *amyloodiniosis* in red drum (*Sciaenops ocellatus*). *Cont. Mar. Sci., Suppl. Vol.*, 50: 183-189.
- Lillie, R. D. and Fulmer, H. M. 1976. Histopathologic technique in practical histochemistry, 4th edn. McGrawHill, New York, 942 pp.
- Montgomery-Brock, M. D., Sylvester, J. Y., Tamaru, C. S. and Brock, J. 2000. Hydrogen peroxide treatment for *Amyloodinium* sp. on mullet (*Mugil cephalus*) fry. Center for Tropical and Sub Tropical Aquaculture, *Aqua. Tips Reg. Notes*, 11(4): 4-6.

- Noga, E. J. and Levy, M. G. 2006. Phylum Dinoflagellata. In: Woo, P. T. K. (Ed.), *Fish diseases and disorders, Volume I, Protozoan and metazoan Infections*, CAB International, Oxford, UK, p. 16-45.
- Paperna, I. 1980. *Amyloodinium ocellatum* (Brown 1931) (Dinoflagellida) infestations in cultured marine fish at Eilat, Red Sea: epizootiology and pathology. *J. Fish. Dis.*, 3: 363-372.
- Paperna, I. 1984a. Reproduction cycle and tolerance to temperature and salinity of *Amyloodinium ocellatum* (Brown 1931) (Dinoflagellida). *Ann. Parasitol. Hum. Comp.*, 59:7-30.
- Paperna, I. 1984b. Chemical control of *Amyloodinium ocellatum* (Brown, 1931) (Dinoflagellida) infections: *In vitro* tests and treatment trials with infected fishes. *Aquaculture*, 38: 1-18.
- Pereira J. C., Abrantes, I., Martins, I., Barata, J., Frias, P. and Pereira, I. 2011. Ecological and morphological features of *Amyloodinium ocellatum* occurrences in cultivated gilthead seabream *Sparus aurata* L.; A case study. *Aquaculture*, 310: 289-297.
- Reed, P. and Francis-Floyd, R. 1994. *Amyloodinium infections of marine fish*. College of Veterinary Medicine, Florida Cooperative Extension Service, Institute of Food and Agricultural Sciences, University of Florida. Fact Sheet VM-90.
- Saraiva, A., Jerónimo, D. and Cruz, C. 2011. *Amyloodinium ocellatum* (Chromalveolata: Dinoflagellata) in farmed turbot. *Aquaculture*, 320: 34-36.
- Schwarz, M. H. and Smith, S. A. 1998. *Getting acquainted with Amyloodinium ocellatum*. Commercial fish and shellfish technology. Virginia Cooperative Extension Fact Sheet Publication 600-200. Virginia Cooperative Extension, Blacksburg, Virginia, USA.